


بِسْمِ اللَّهِ
الرَّحْمَنِ
الرَّحِيمِ





Hypertensive emergencies and urgencies

By

Gamal Fheem, MD

Professor of cardiovascular medicine

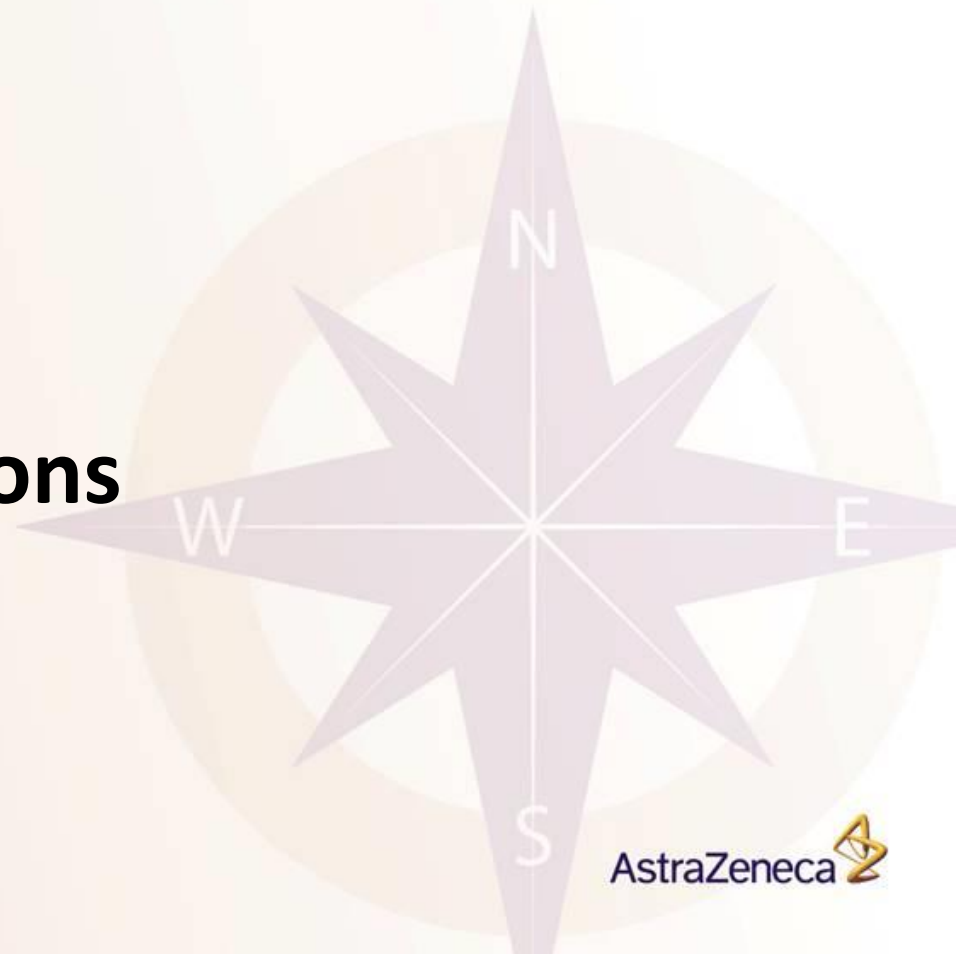Mansoura university

31 march 2014

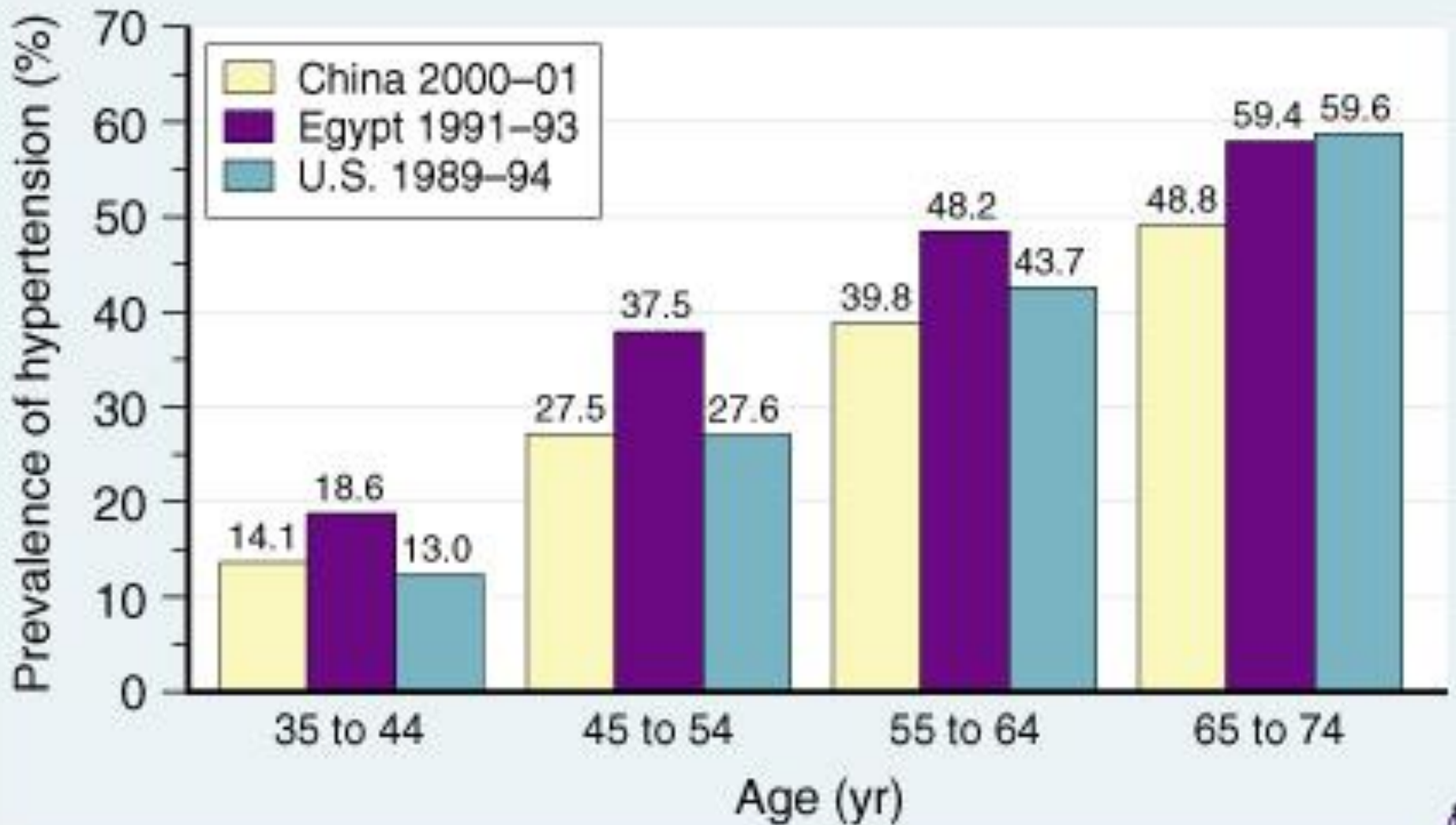


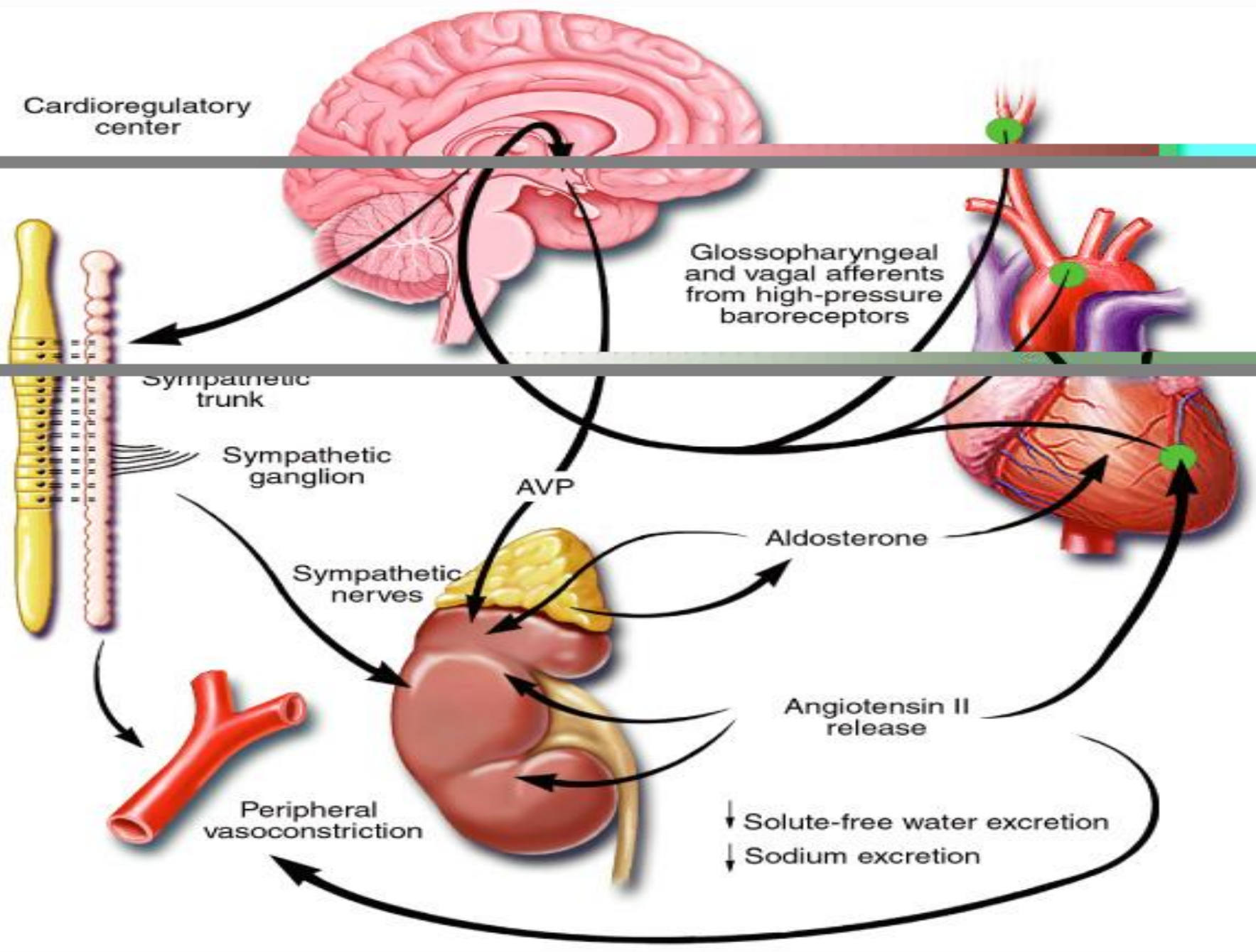
outline

- **Introduction**
- **Definitions**
- **Incidence**
- **Pathophysiology**
- **Clinical manifestations**
- **Therapy**



International Society of Hypertension prevalence of hypertension among three populations







Definitions: Hypertensive Crisis

- **Hypertensive Urgency:**
 - SBP >180 or DBP>110 without TOD
- **Hypertensive Emergency (Malignant HTN):**
 - SBP >180 or **DBP>110** or accelerated HTN + TOD
 - TODs:
 1. Brain: Hypertensive encephalopathy/edema, ICH, ischemic stroke
 2. Retina: Grade IV retinopathy (papilledema)
 3. CVS: ACS, Acute pulmonary edema, CHF, Aortic dissection
 4. Kidneys: accelerated nephrosclerosis, nephritic syndrome
 5. Blood: MAHA, HELLP
 6. Pregnancy: HELLP, Eclampsia

Epidemiology of APS

- Recently, came down from 3% to **< 1 % of hypertensive** patients(better management).
- ▶ **1/4** of the **acute medical** cases in ER
- ▶ Hypertensive **urgencies 76 %** of the hypertensive crises while **emergencies** were **24%**.
- Common in the black & elderly patients.
- Previous **history of HTN and treatment.**



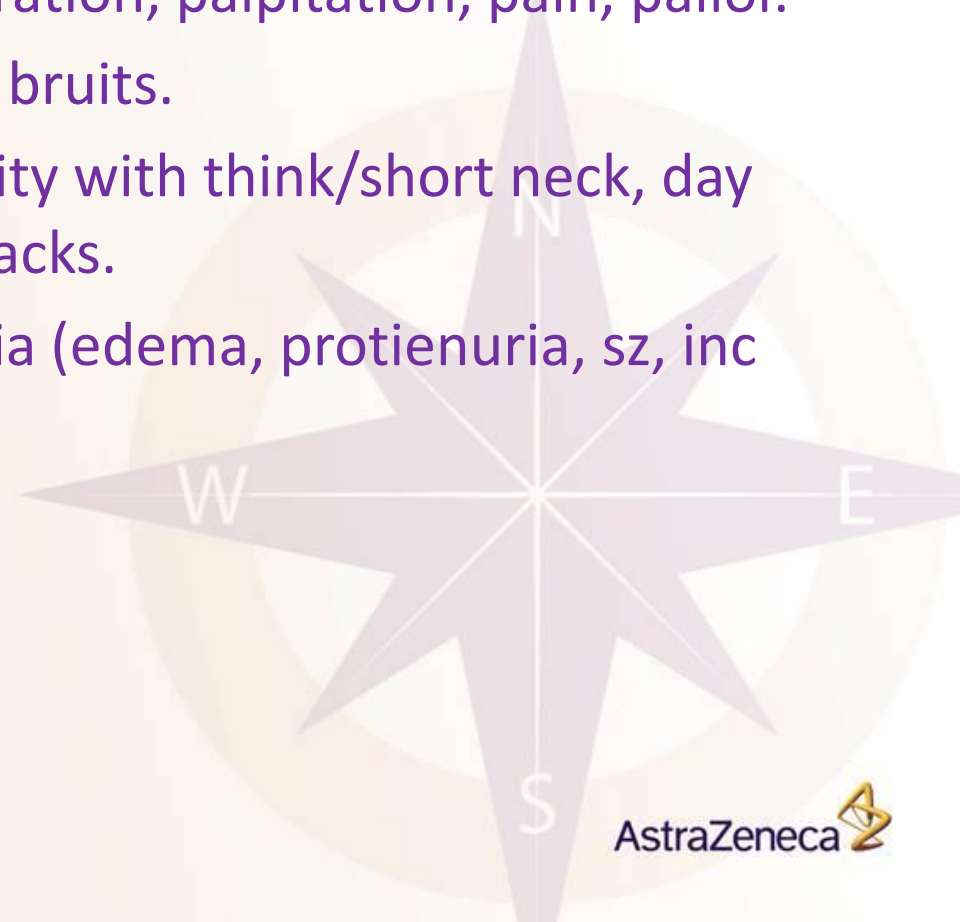
Clinical Findings

A) Of predisposing disease:

- **Thyrotoxicosis/Thyroid storm.**
- **Hypothyroidism/Myxedema,goiter.**
- **Hyperparathyroidism:** hypercalcemia (psychosis, constipation, inc QTc, cataract, dystrophic calcifications of soft tissue (X-ray).
- **Cushing's:** Cushinoid.



- **Conn's:** hypokalemic metabolic alkalosis.
- **Pheochromocytoma:** perspiration, palpitation, pain, pallor.
- **Renal artery stenosis:** Renal bruits.
- **Pickwickian Syndrome:** Obesity with thick/short neck, day time somnolence, apnea attacks.
- **Pregnancy:** HELLP, Eclampsia (edema, proteinuria, sz, inc DTR).

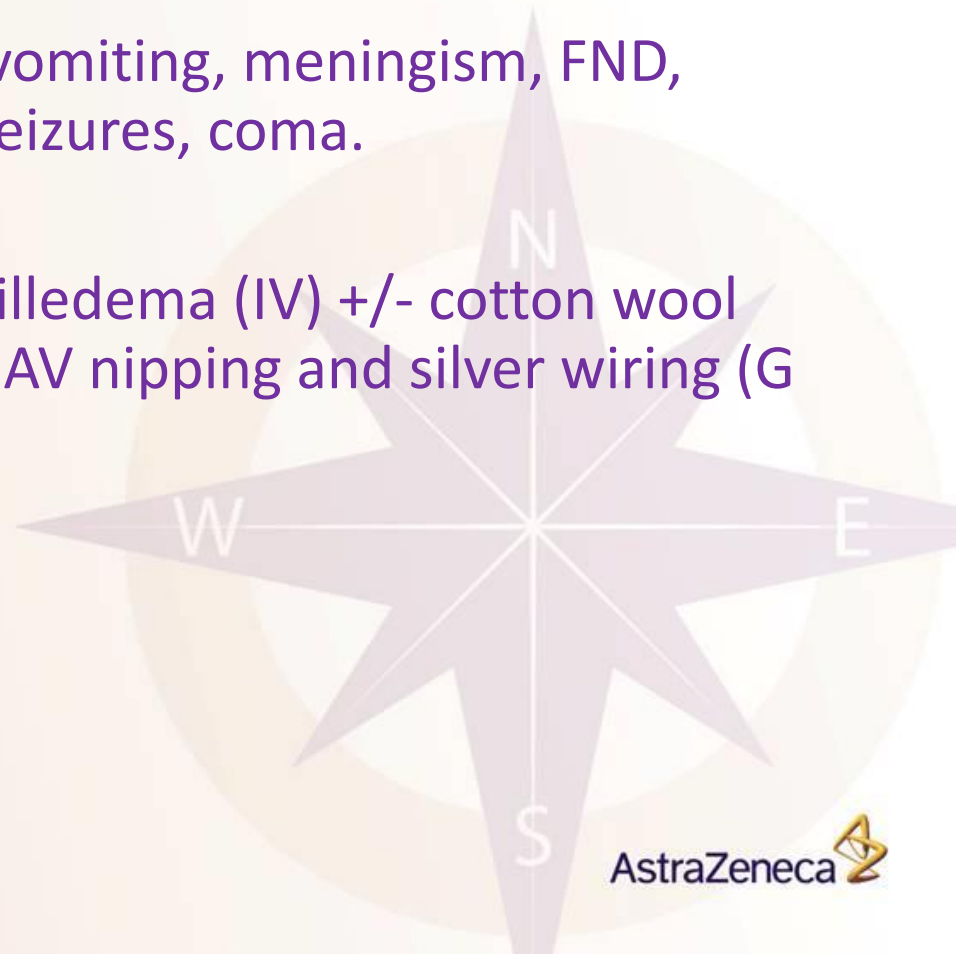




Clinical Findings

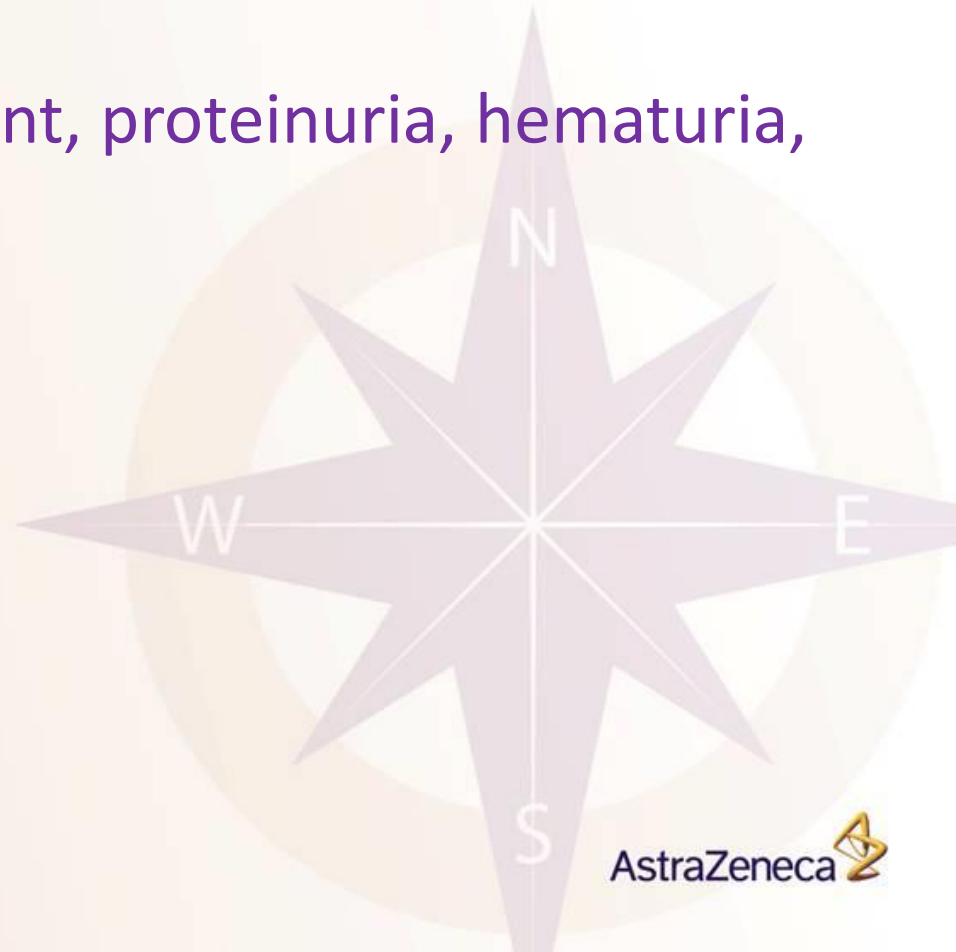B) Of Complications (TOD):

- **Brain:** Headache, nausea, vomiting, meningism, FND, delirium, decreased LOC, seizures, coma.
- **Retina:** blurred vision, papilledema (IV) +/- cotton wool exudate, flame shape hge, AV nipping and silver wiring (G I-III in chronic Htn).





- **CVS:** chest pain, ACS (MR, ECG, trop), CHF
- **Kidneys:** active sediment, proteinuria, hematuria, tubular casts.





Hypertensive Emergency/Urgency: Differential Diagnosis

- Untreated or suboptimally treated essential hypertension (most common)
- Renal parenchymal disease
 - Including microvascular thrombosis
 - ✓ TTP, HUS, vasculitis, acute glomerulonephritis
- Renal vascular disease (Renal artery stenosis)
- Pregnancy Induced Hypertension/Pre-eclampsia/Eclampsia
- Endocrine:
 - Pheochromocytoma (or exogenous catecholamines)
 - Cushing's syndrome
 - Renin-secreting tumors



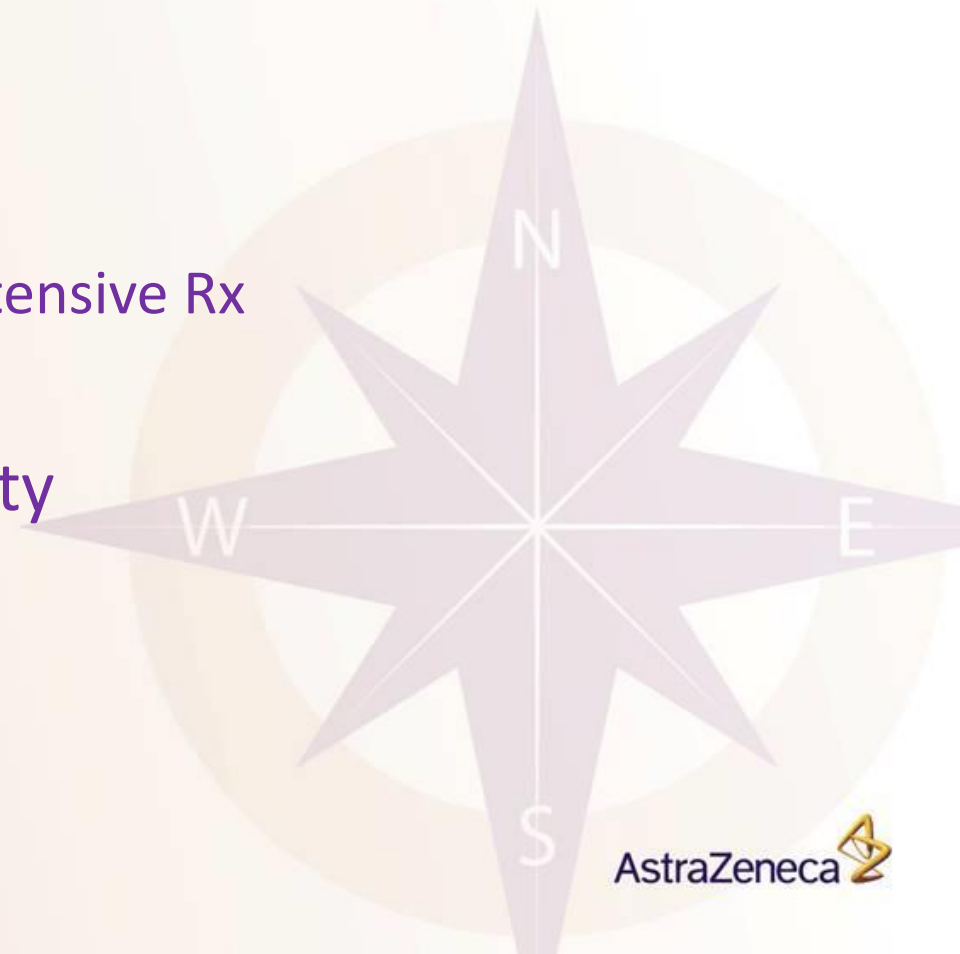○ Drugs

- Sympathomimetic consumption/overdose (SPH/RCH)
- Cocaine/crack
- Amphetamines
- PCP
- Withdrawal from antihypertensive Rx
- MAOI interactions

○ Autonomic hyper-reactivity

- Guillan-Barre
- Autonomic dysreflexia
- Porphyria

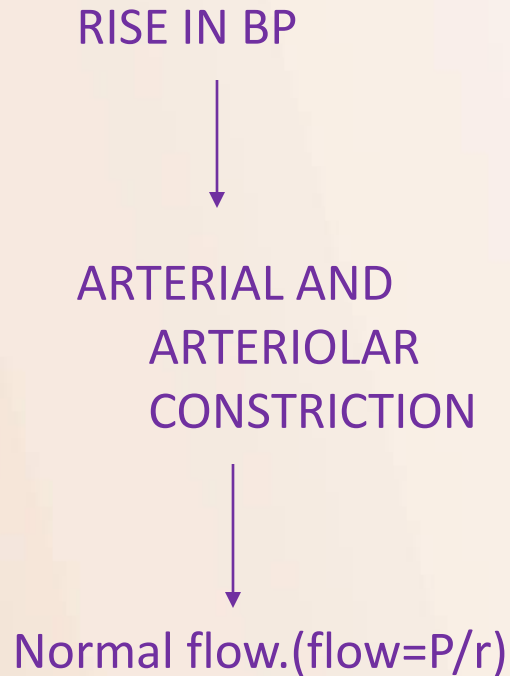
○ Elevated ICP



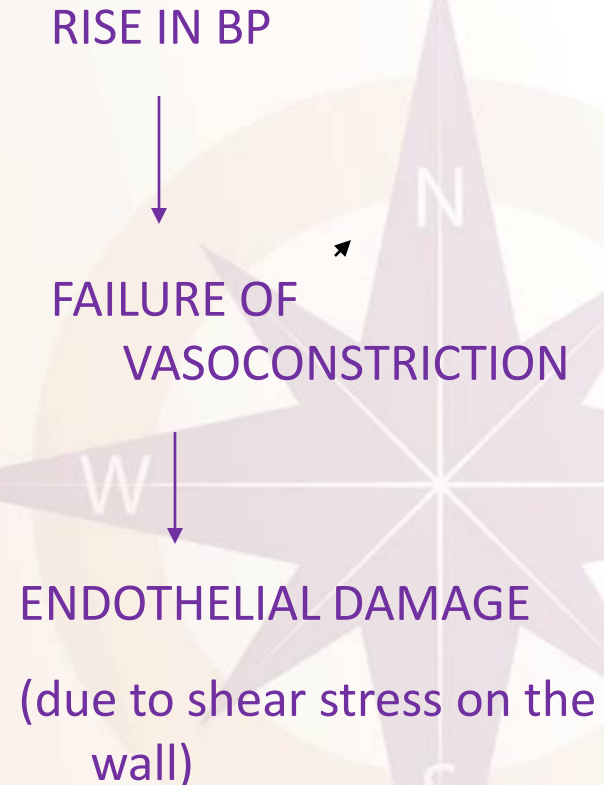


PATHOPHYSIOLOGY

NORMAL AUTOREGULATION



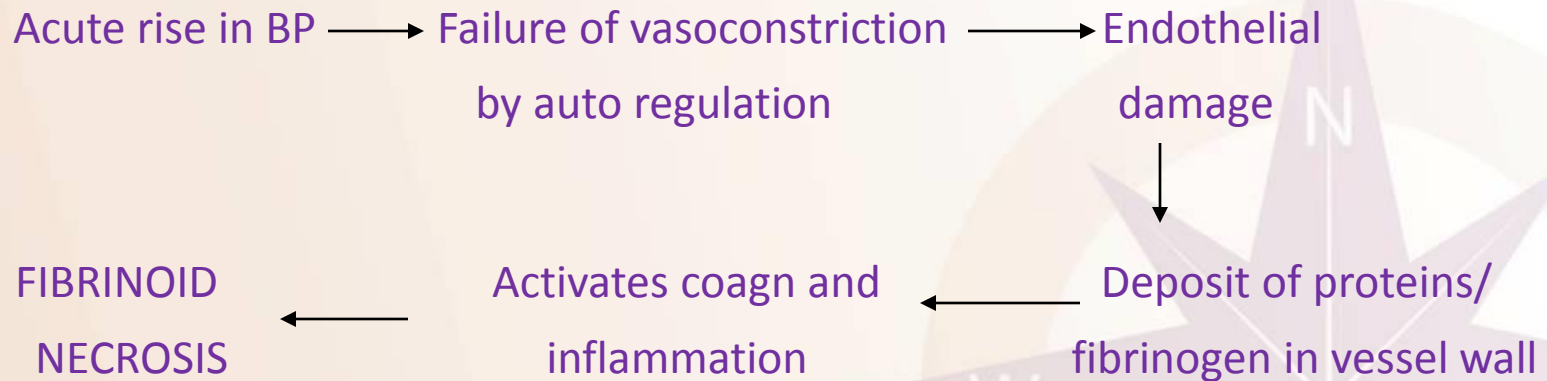
AUTOREGULATION FAILURE





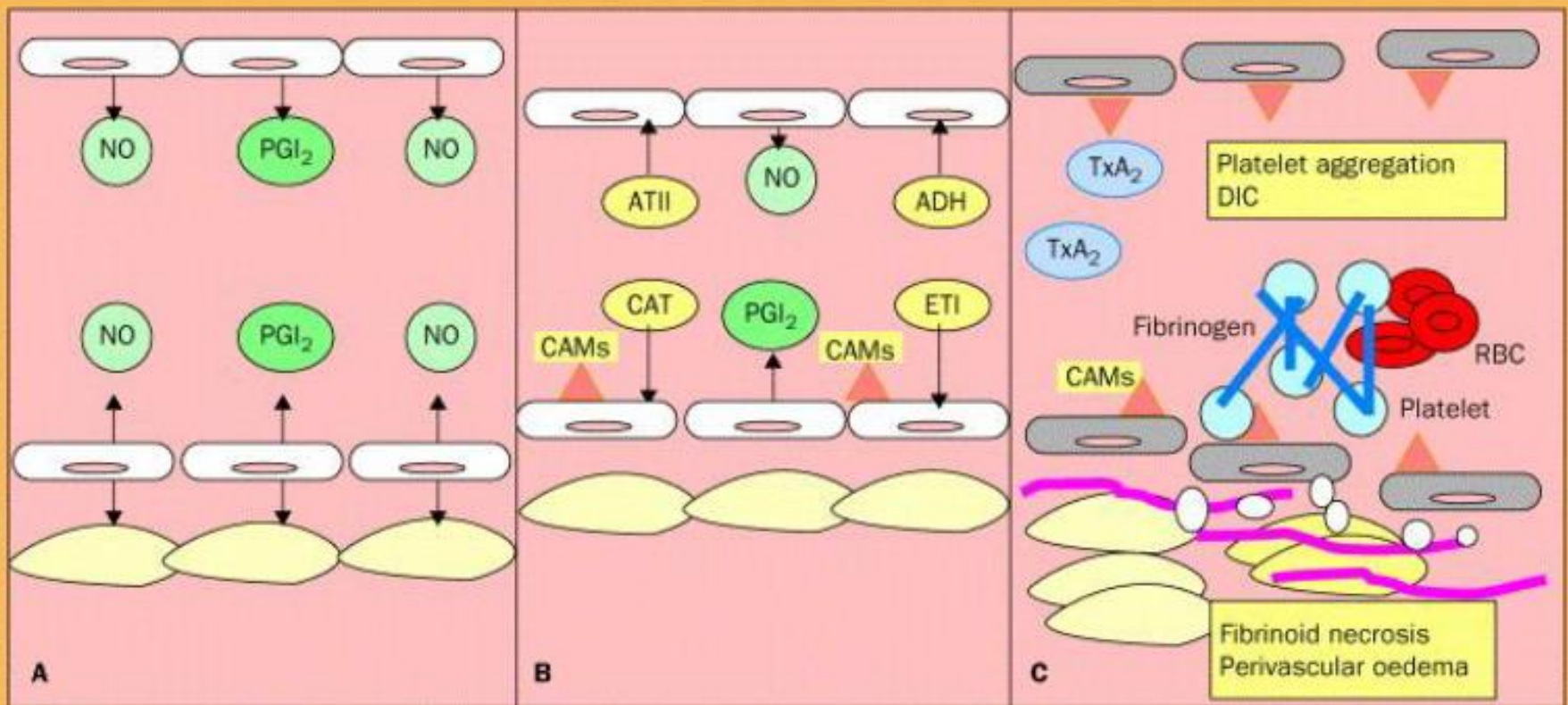
PATHOPHYSIOLOGY

- $BP = PVR * CO (SV * HR)$
- Rate at which MAP rises more important than absolute rise.



- RAAS plays an important role in initiating and perpetuating BP rise by causing vasoconstriction and fluid retention.

Vasculopathy of Acute HTN Syndrome



Normotension
or
chronic hypertension



Hypertensive
urgency

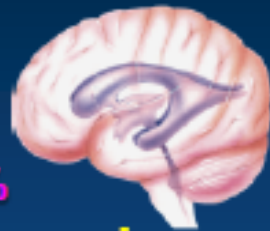

Hypertensive
emergency

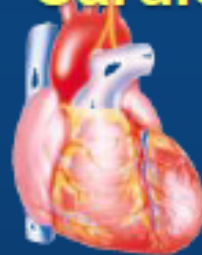Hypertensive Emergencies

End Organ Damage

Hypertensive encephalopathy 16%
Cerebral infarct 24%
Hemorrhage 4.5%

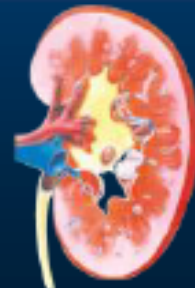

Cardiopulmonary

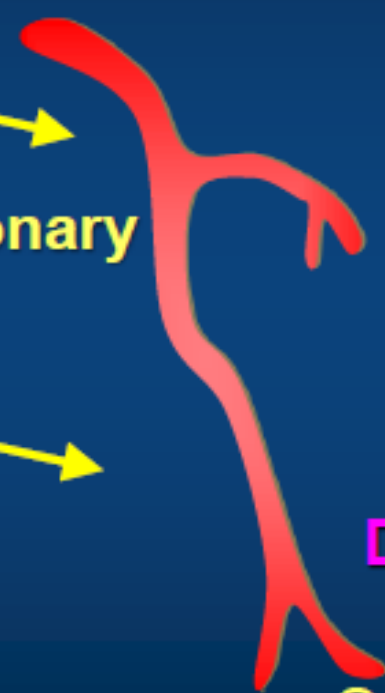

Acute heart failure 23%

Decompensated Heart Failure



Acute Renal Failure



ACS

Aortic Dissection

Ocular

Exudates
Papilledema
Retinal hemorrhages

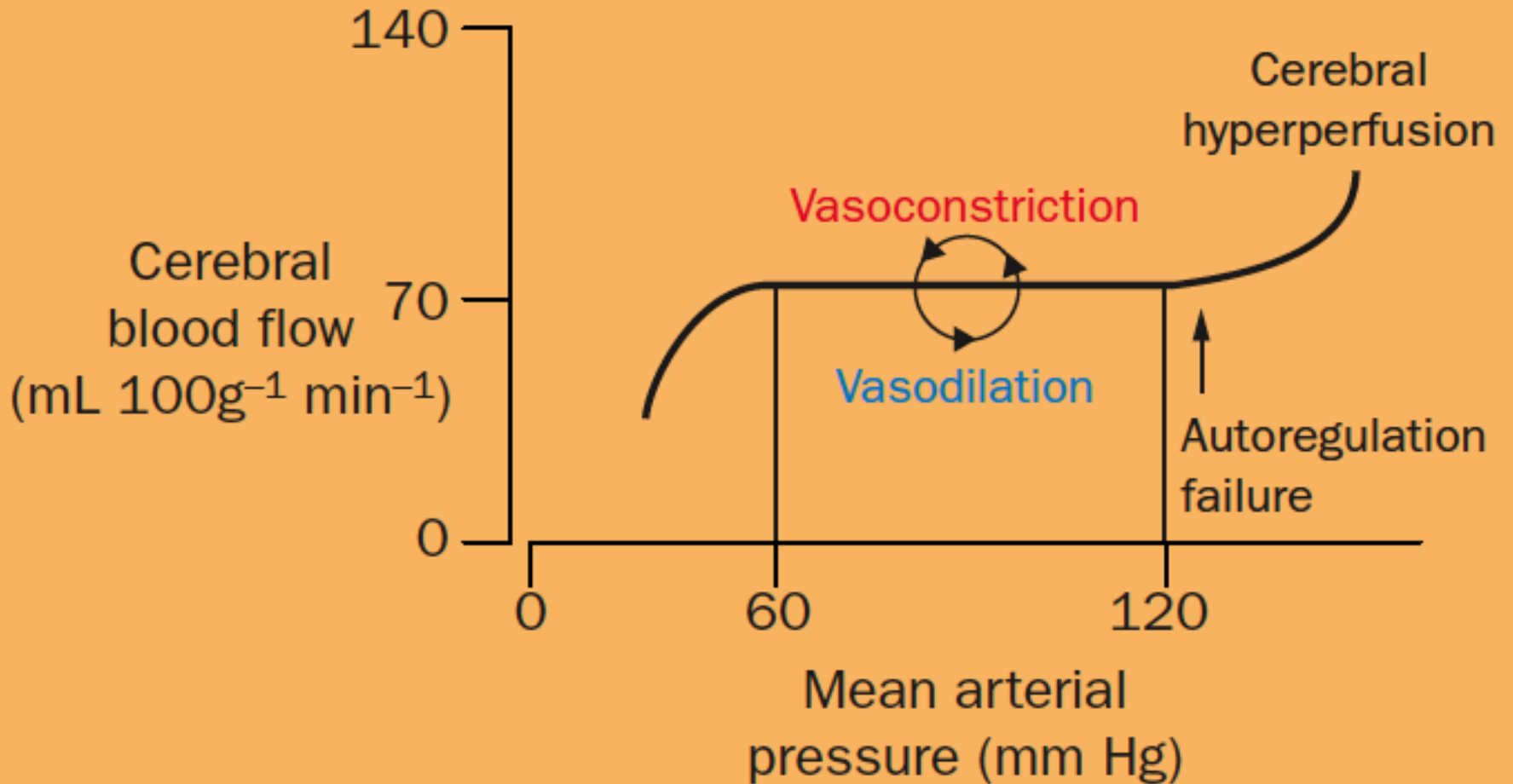


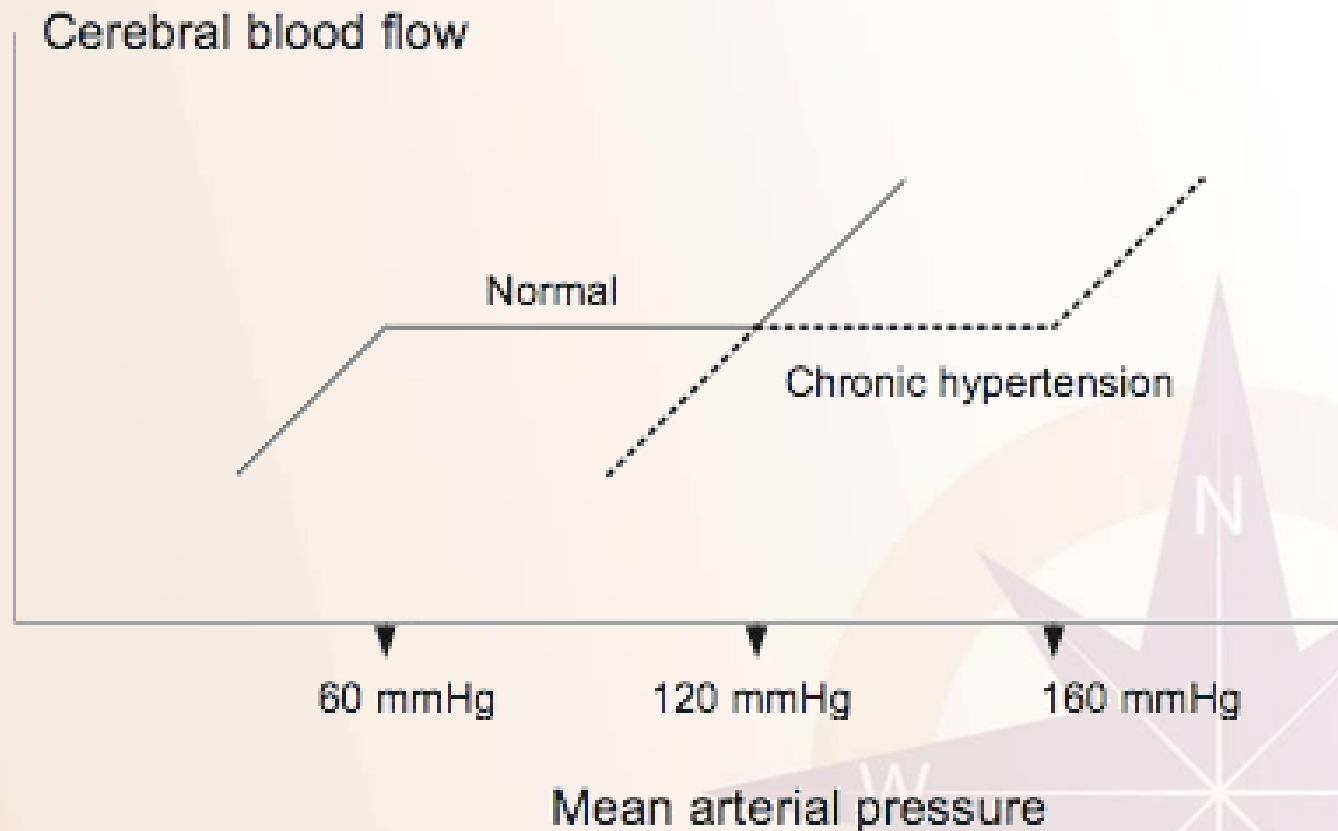
CENTRAL NERVOUS SYSTEM

- The CNS is affected as the elevated BP overwhelms the normal cerebral autoregulation.
- Under normal circumstances, with an increase in BP, cerebral arterioles vasoconstrict and cerebral blood flow (CBF) remains constant.
- During a hypertensive emergency, the elevated BP overwhelms arteriolar control over vasoconstriction and autoregulation of CBF.
- This results in transudate leak across capillaries and continued arteriolar damage.
- Subsequent fibrinoid necrosis causes normal autoregulatory mechanisms to fail.
- The end result of loss of autoregulation is hypertensive encephalopathy.



Cerebral Autoregulation



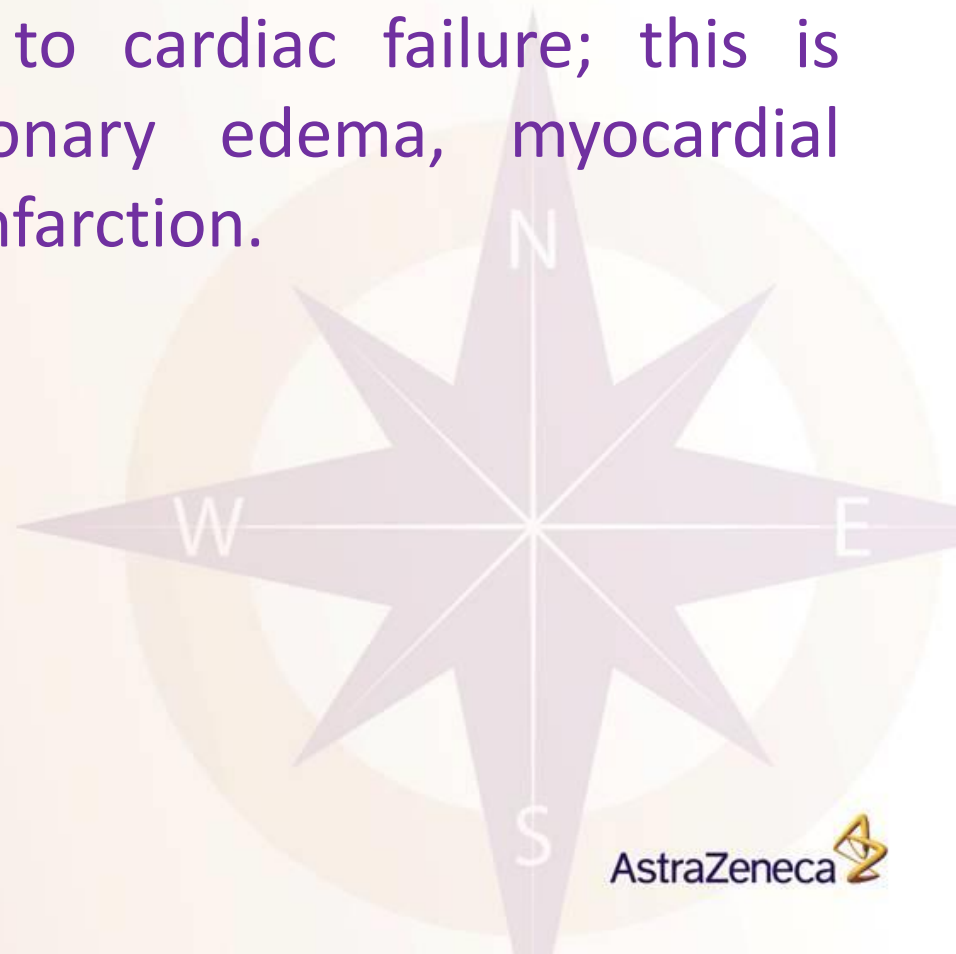


Cerebral autoregulation in normotensive and chronically hypertensive patient.



CARDIOVASCULAR SYSTEM

- The cardiovascular system is affected as increased cardiac workload leads to cardiac failure; this is accompanied by pulmonary edema, myocardial ischemia, or myocardial infarction.





RENAL SYSTEM

- The renal system is impaired when high BP leads to arteriosclerosis, fibrinoid necrosis, and an overall impairment of renal protective autoregulation mechanisms.
- This may manifest as worsening renal function, hematuria, red blood cell (RBC) cast formation, and/or proteinuria.



Investigations

- Book for history and physical examination
 - Need for resuscitation (LOC, arrhythmias, pulmonary edema, seizures, tearing chest pain, etc)
 - History of HTN (and detailed history of Rx, compliance and course of care as available), drug use, pregnancy (and pregnancy hx), systemic vascular disease, etc.
 - Medications including OTC.



Investigations (cont.)

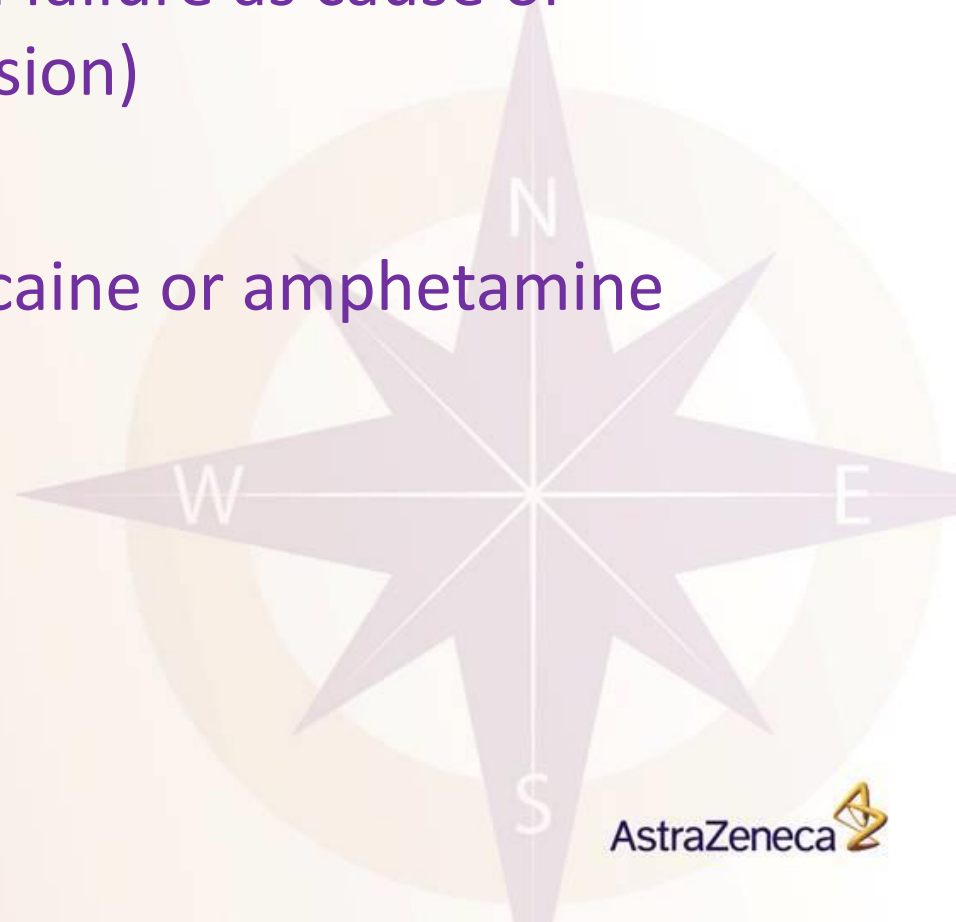
○ Physical exam:

- Vital signs... HR as well as BP, to guide therapy
 - ✓ Arterial line, particularly if IV medications are used
- Neuro (LOC/encephalopathy, seizures, focal deficits)
- Cardiovascular (heart failure, volume status, arrhythmias)
- Respiratory (pulmonary edema)
- Abdominal exam
 - ✓ Systolic/diastolic bruits, palpable aneurysm
 - ✓ masses occupying the entire epigastrium and invading the liver and aorta (hey, you never know)



Investigations (cont.)

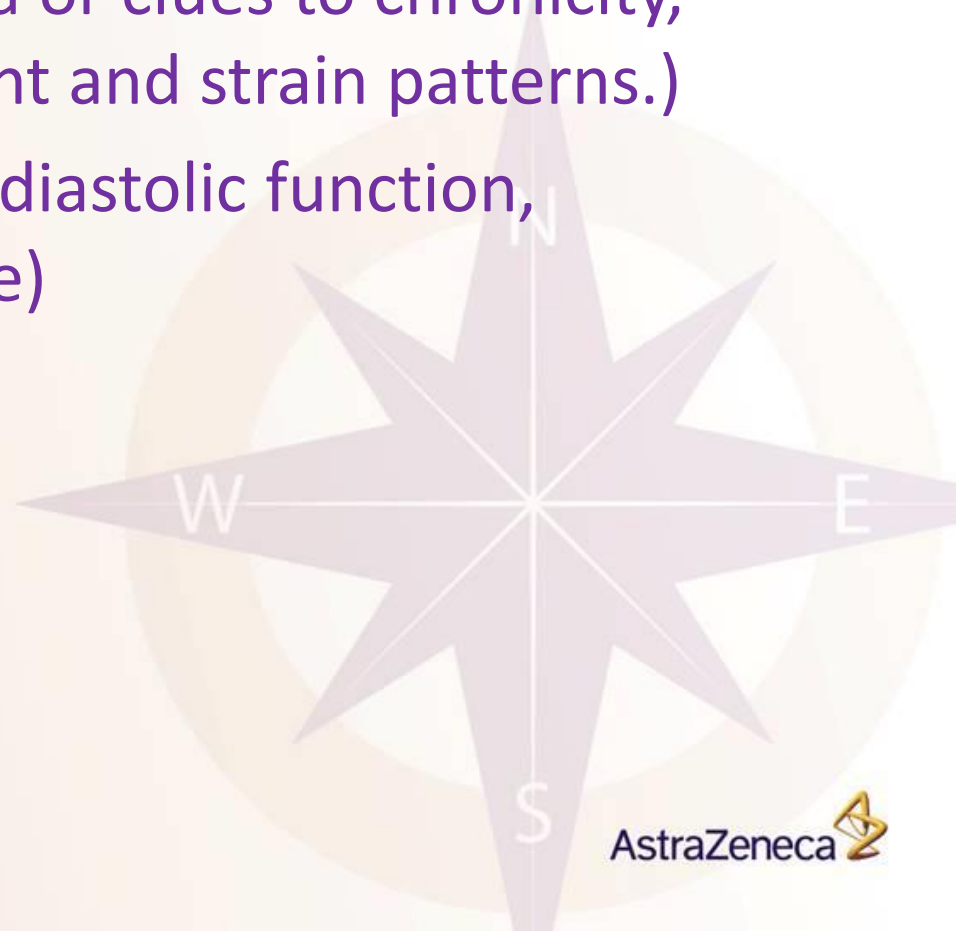- CBC (Hemolytic anemia)
- 'Lytes, renal indices (renal failure as cause or consequence of hypertension)
- B-hcg
- If Hx unclear, urine for cocaine or amphetamine metabolites





Investigations (cont.)

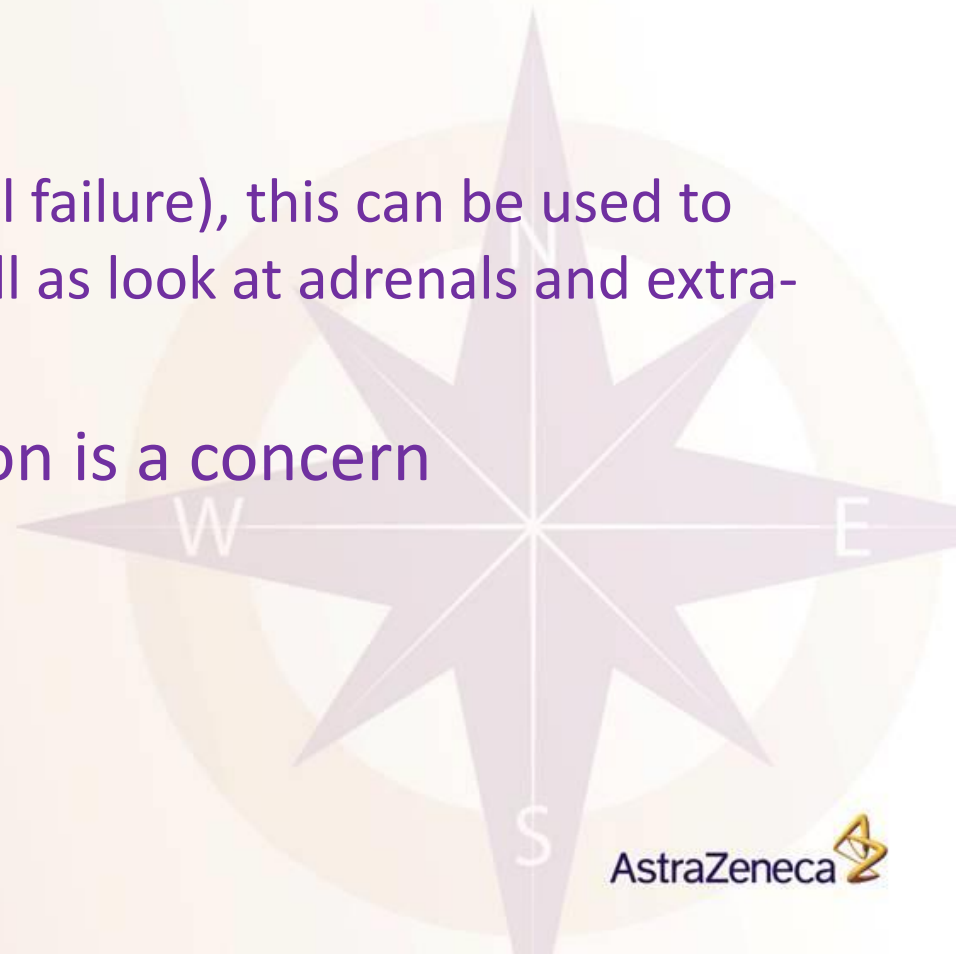
- Chest X-ray (pulmonary edema)
- ECG (Myocardial ischemia or clues to chronicity, such chamber enlargement and strain patterns.)
- Echocardiogram (systolic/diastolic function, hypertrophy, chamber size)



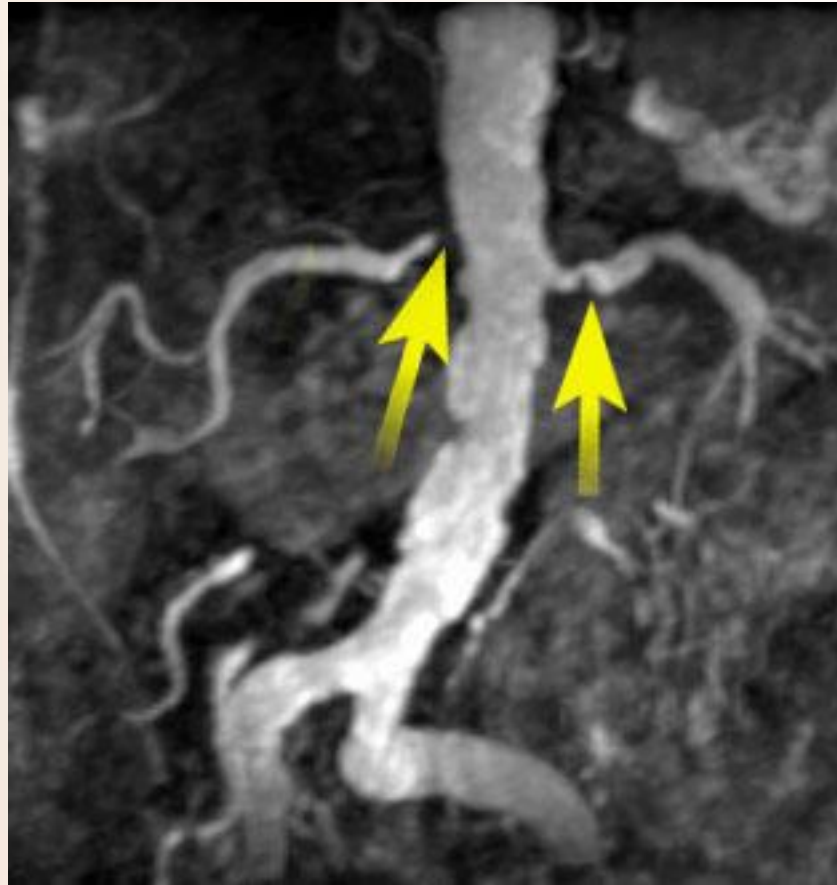


Investigations (cont.)

- CT Brain: intracranial hemorrhage, tumor, posterior leukoencephalopathy
- CT Abdomen/Pelvis
 - If contrast is possible (renal failure), this can be used to assess renal arteries as well as look at adrenals and extra-adrenal masses
- CT Chest if aortic dissection is a concern



CT angiogram





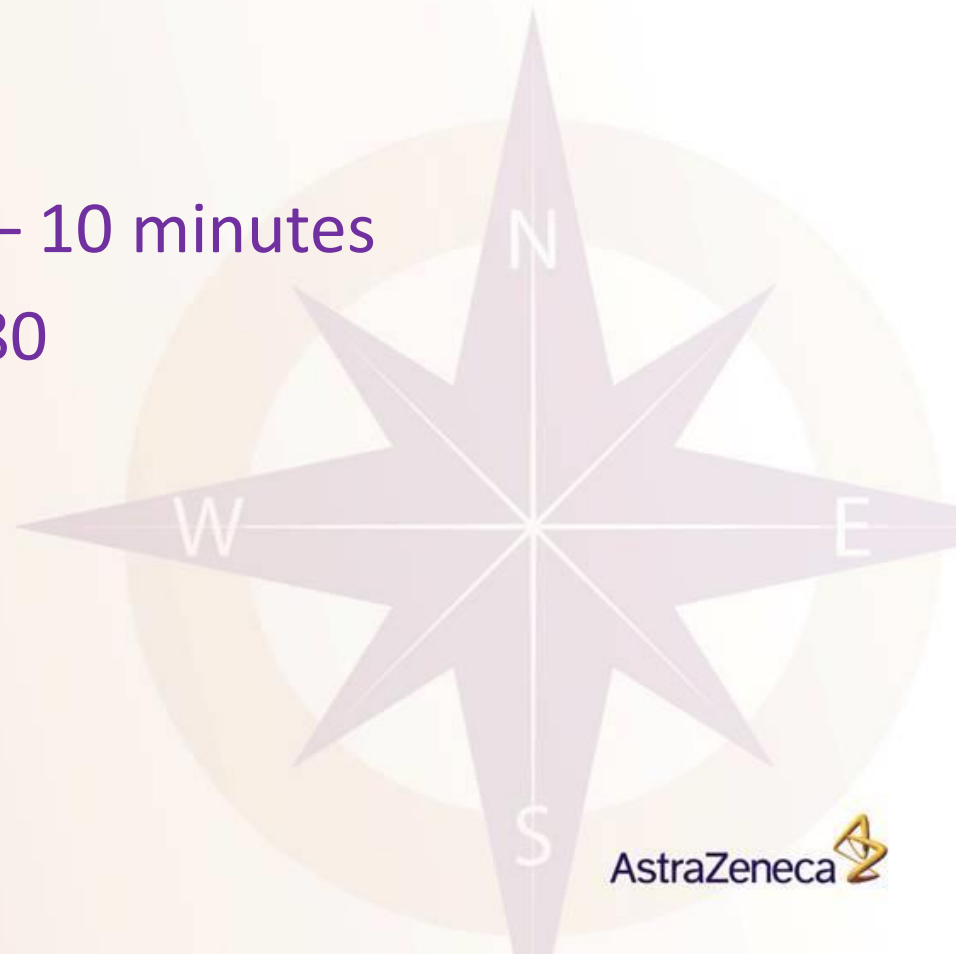Urgency

- Rapid reduction in BP may associated with significant morbidity; organ hypoperfusion
 - Ischemia
 - Infarction
- Lower gradually over 24 – 48 hours
- Oral medications are advisable
- Patients may have pressure induced natriuresis
 - consider volume repleting to prevent precipitous drops



Hypertensive Emergency

- Reduce DBP by 10 – 15%, or to ~ 110 mm Hg over 30 – 60 minutes.
- Aortic Dissection
 - Rapid lowering over 5 – 10 minutes
 - SBP < 120 and MAP < 80



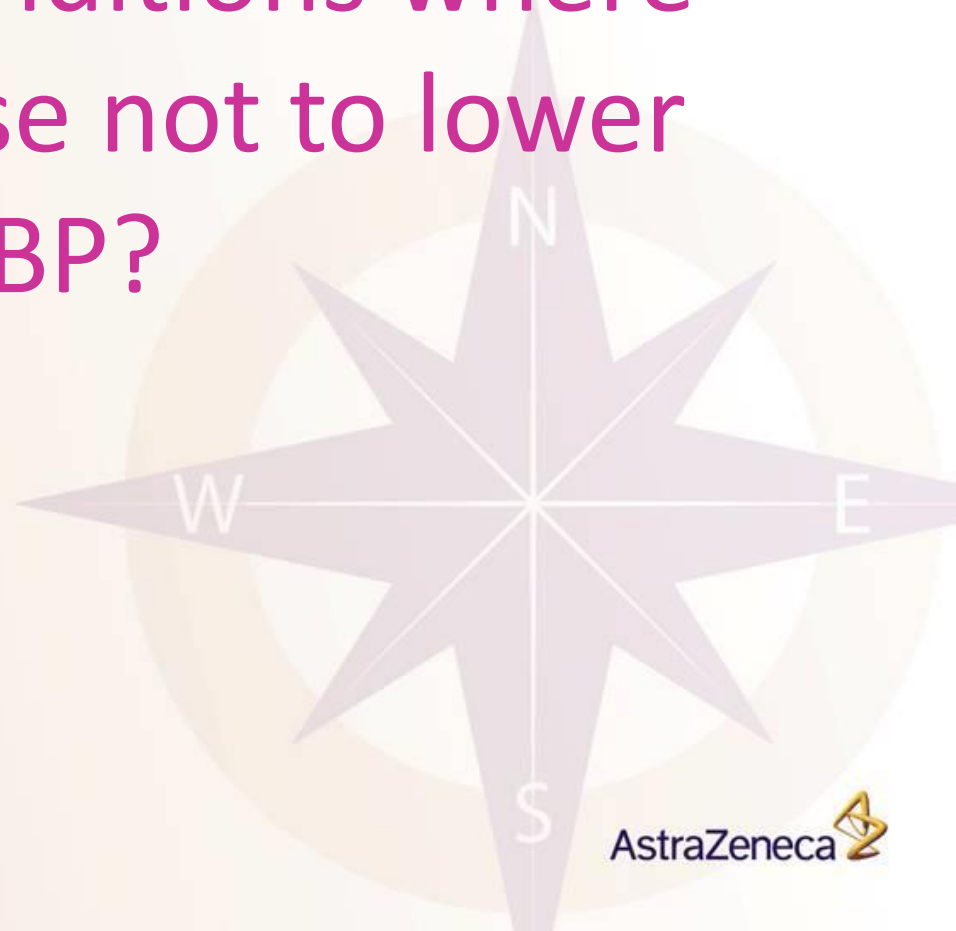

RAPID BP REDUCTION

- Acute myocardial ischemia: IV NTG, b-blockers, ACE inhibitors.
- CHF with pulmonary edema: iv NTG, furosemide, morphine
 - Acute aortic dissection: iv nitroprusside + b-blockers or iv trimethaphan + b-blockers.
 - Hypertensive encephalopathy or sub-arachnoid hemorrhage: iv nitroprusside, labetalol or nimodipine.
 - MAO-tyramine interactions with acute hypertension: iv phentolamine.



Are there any conditions where
you would choose not to lower
their BP?





CVA's

- Ischemic CVA
 - Protective physiologic response to maintain CPP
 - Impaired auto-regulation
 - Some evidence for induced HTN
 - Treat if:
 - ✓ Thrombolysis (SBP/DBP < 185/110)
 - ✓ End organ damage
 - ✓ SBP > 220, DBP >120 (critical point at which sphincter tone becomes unbearable)

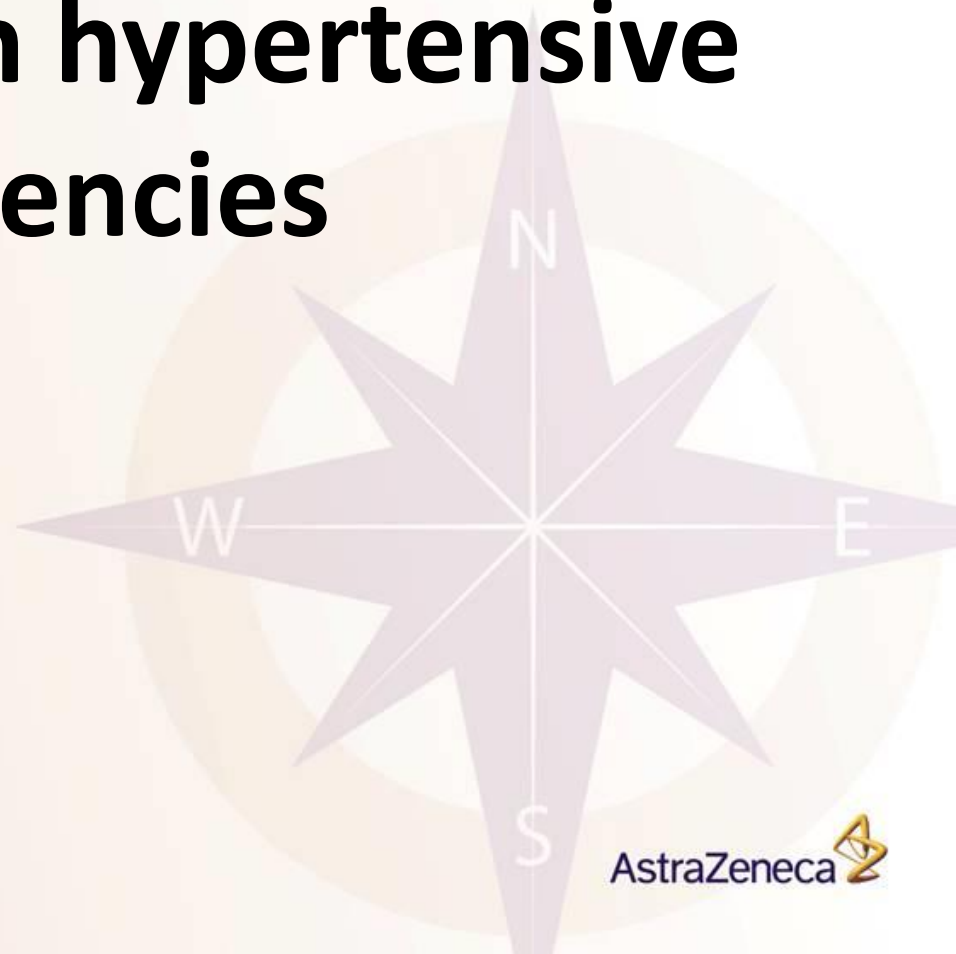


CVA's

- Hemorrhagic CVA
 - Controversial topic
 - No evidence HTN leads to increased size of ICH, but there is an association
 - Evidence suggests lowering BP rapidly leads to increased mortality
 - Maintain SBP < 200, DBP < 130
 - Lowering MAP ~ 15% does not seem to reduce CBP



Agents used in hypertensive emergencies





Optimal characteristics of drugs used in hypertensive emergencies

1. Easily titratable:
 - Fast onset
 - Short duration of action
2. Minimal reflex activation of counterregulatory systems (sympathetic, RAAS)
3. Devoid of side-effects or drug interactions
4. Lack of tolerance or tachyphylaxis



Pharmacodynamic characteristics of antihypertensive drugs

Drug	Route	Dosage	Onset	Duration
Nitroprusside	i.v. infusion	0.25-10 mcg/kg/min	Immediate	1-2 min
Labetalol	i.v. bolus	10-20 mg up to 80 mg every 10 minutes	3-5 min	3-6 h
	i.v. infusion	0.5-2 mg/min		
Nitroglycerin	i.v. infusion	5-300 mcg/min	1-2 min	1-3 min
Nicardipine	i.v. infusion	5-15 mg/h	5-10 min	15-40 min
Fenoldapam	i.v. infusion	0.1-1.6 mcg/kg/min	15 min	30-60 min
Esmolol	i.v. loading	1 mg/kg for 1 min	1-2 min	20-30 min
	i.v. infusion	150-300 mcg/kg/min		
Phentolamine	i.v. bolus	5-10 mg every 10 min	1-2 min	10-30 min
Enalaprilat	i.v. bolus	0.625-1.25 every 6h	10-15 min	6-8 h
Hydralazine	i.v. bolus	5-20 mg	10-30 min	3-6 h



Nitroprusside

- The prototype of a short-acting easy-to-titrate arteriolar and venous vasodilator.
- Most common adverse effect is **hypotension** which can be treated by reducing dosage and administering fluids if needed (lasts 1-2 min).
- Other adverse effects include **reflex tachycardia** and **cyanide/thiocyanate toxicity**.



Nitroprusside

- Nitroprusside is metabolized non-enzymatically through combination with hemoglobin to produce cyanomethemoglobin.
- A mitochondrial enzyme in the liver (rhodanase), catalyzes the reaction of cyanide with thiosulphate to produce thiocyanate.
- Thiocyanate is then excreted in the urine.
- So hepatic insufficiency leads to cyanide accumulation whereas renal insufficiency leads to thiocyanate accumulation.



Nitroprusside

- Cyanide toxicity manifests as lactic acidosis, confusion, and hemodynamic instability.
- Other signs include abdominal pain, delirium, headache, nausea, muscle spasms and restlessness.
- Cyanide toxicity is best prevented by avoiding large doses (>3mcg/kg/min) of nitroprusside for greater than 72h, especially in patients with hepatic or renal dysfunction.
- Maximal doses of 10 mcg/kg/min should not be administered for more than 10 minutes.



Labetalol

- A non-selective β -blocker with associated α -blocking activity, in a 7 to 1 ratio in i.v. formulation.
- Reduces peripheral vascular resistance with mild reduction in heart rate while maintaining cardiac output.
- Contraindicated in reactive airway disease or second to third degree heart block.
- Should be used with caution in patients with second to third degree heart block.



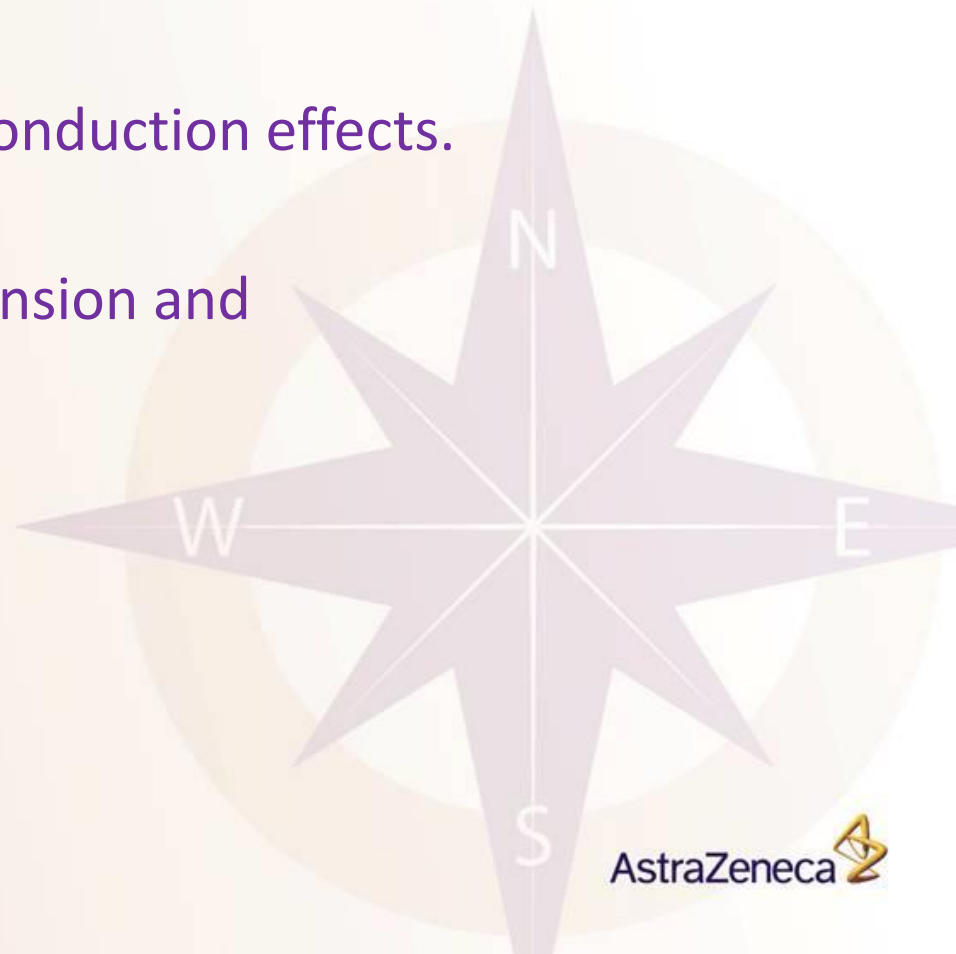Nitroglycerin

- A venous and coronary artery dilator.
- Can dilate systemic arteries at higher doses.
- Indicated in patients with acute coronary syndromes; has also been used in perioperative hypertension.
- Side effects include headache, nausea, bradycardia, hypotension, and methemoglobinemia.
- Prolonged use may cause tachyphylaxis.



Nicardipine

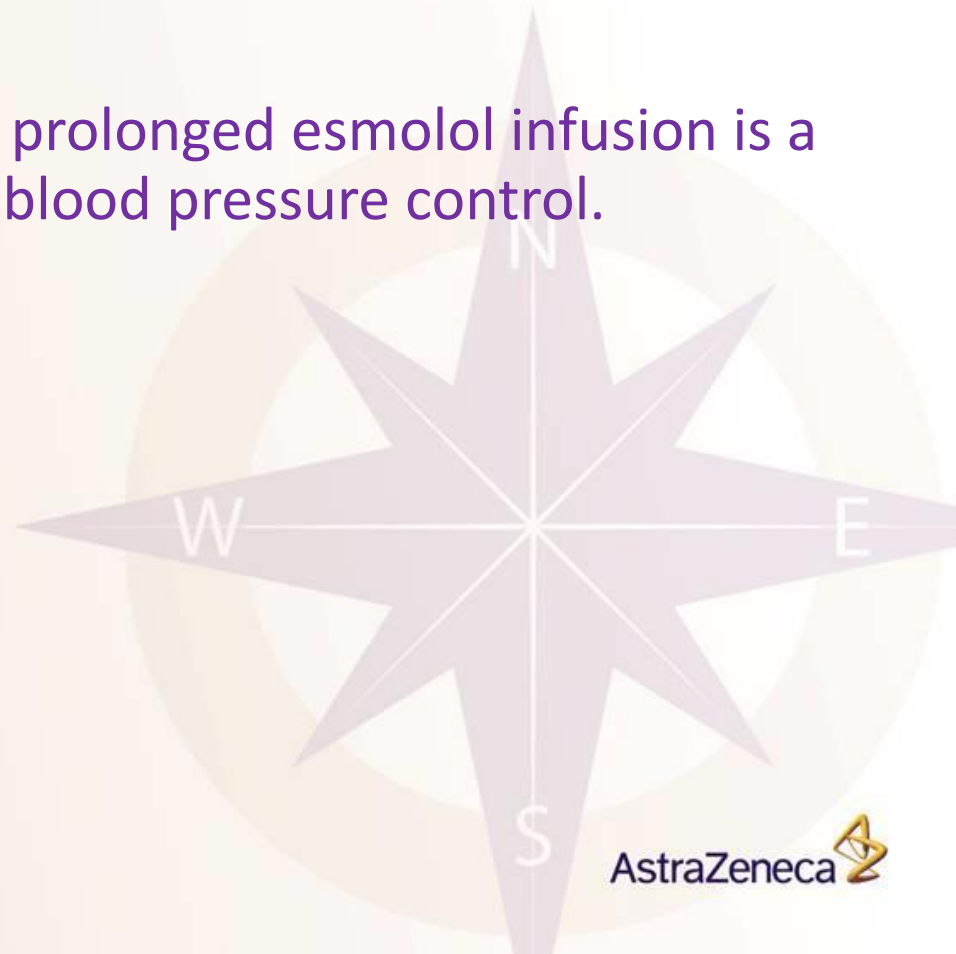
- A dihydropyridine CCB with systemic and coronary vasodilating effects.
- No negative inotropic or a-v conduction effects.
- Used in perioperative hypertension and eclampsia/preeclampsia.





Esmolol

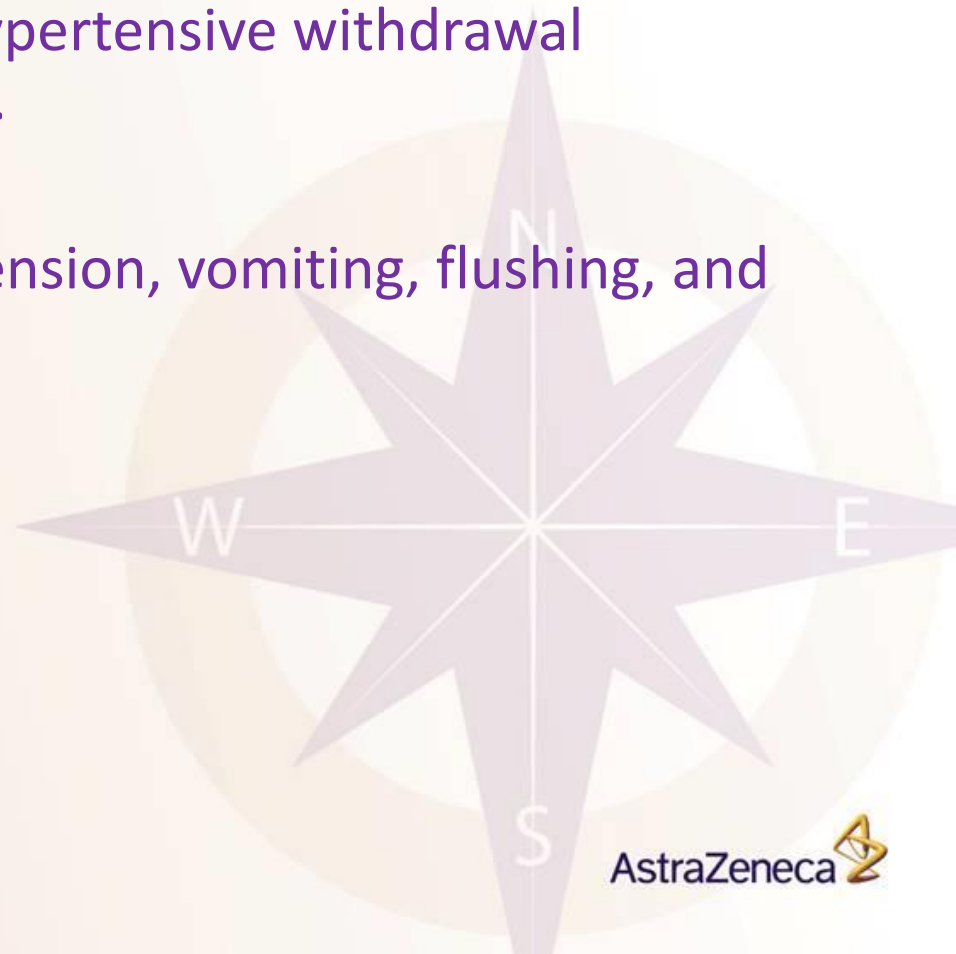
- Short-acting cardioselective β -blocker that can be used in perioperative hypertension and tachycardia.
- If no other agents are used , a prolonged esmolol infusion is a relatively expensive means of blood pressure control.





Phentolamine

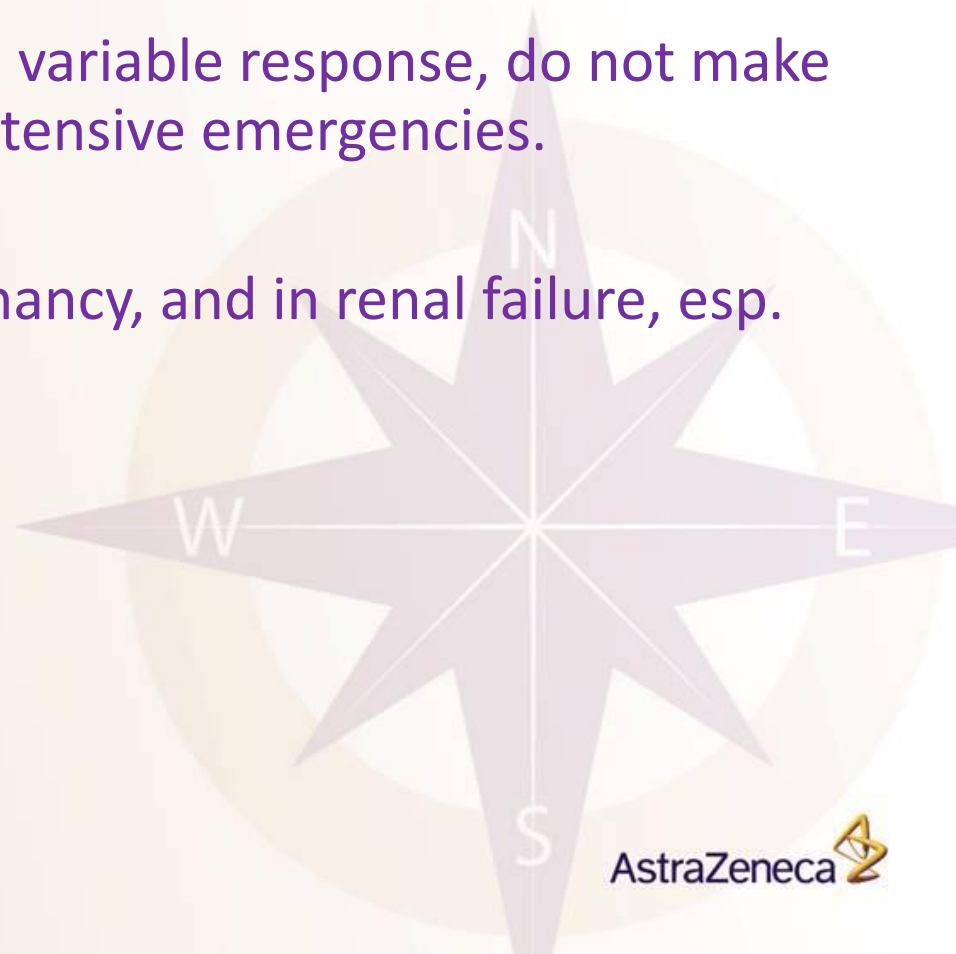- Peripheral α -blocker indicated for management of hypertensive emergencies associated with catecholamine excess such as pheo, maoi interaction, antihypertensive withdrawal syndrome, and cocaine abuse.
- Can cause tachycardia, hypotension, vomiting, flushing, and angina.





Enalaprilat

- The IV formulation and active metabolite of enalapril.
- Its long duration of action and variable response, do not make it an ideal candidate for hypertensive emergencies.
- Contraindicated during pregnancy, and in renal failure, esp. in renal artery stenosis.



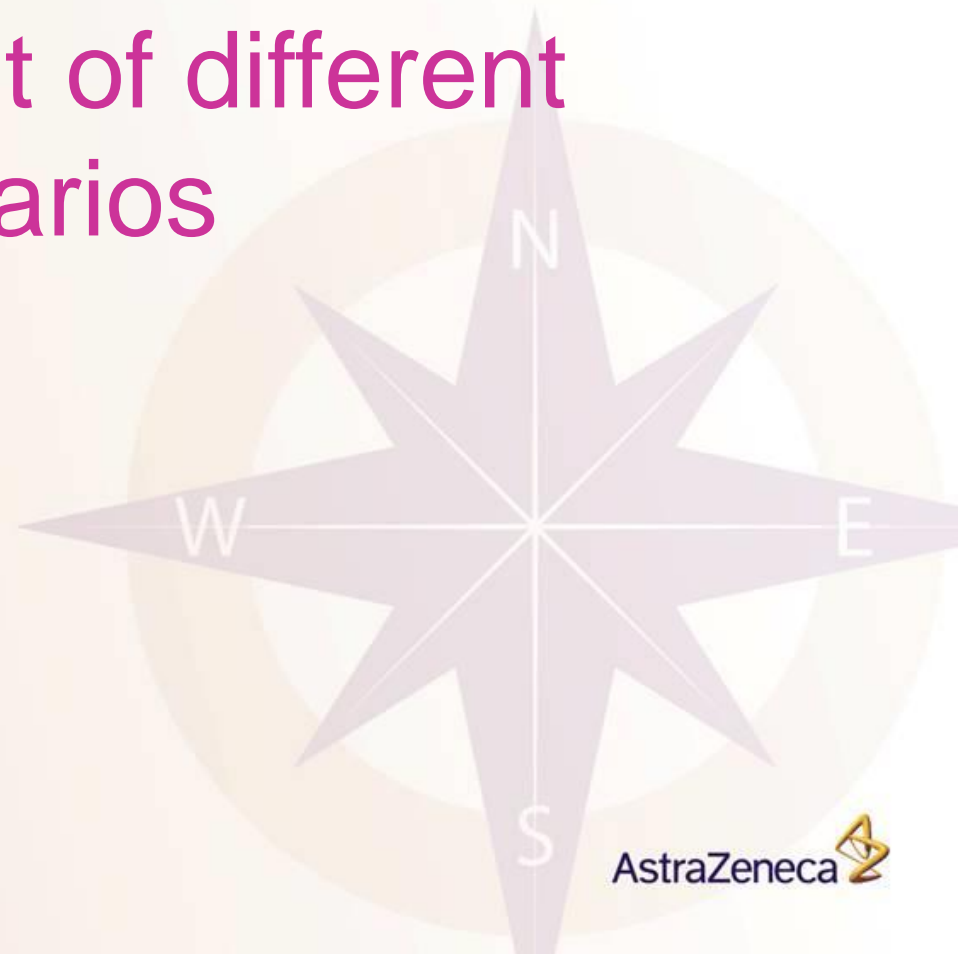

Hydralazine

- An arteriolar vasodilator.
- Difficult to use due to its variable magnitude and rate of response.
- Improves placental blood flow so good for preeclampsia/eclampsia
- Side effects include tachycardia, and increased CO/myocardial oxygen consumption.
- Should therefore not be used in aortic dissection or myocardial ischemia.



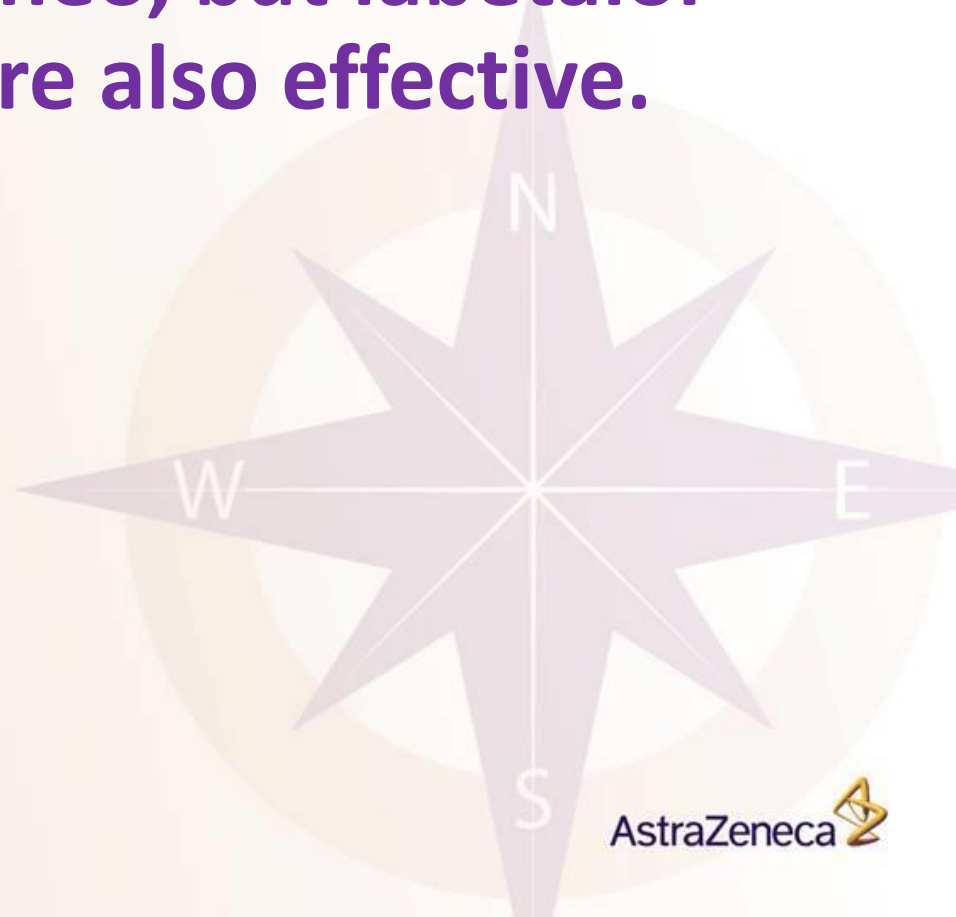Management of different scenarios





Pheochromocytoma

- Phentolamine has classically been the drug of choice for pheo, but labetalol and nitroprusside are also effective.





Aortic dissection

- Goal is to reduce the shear force, and therefore the dP/dt .
- Goal is an SBP of 100-110 achieved with a beta-blocker and an easily titratable vasodilator if necessary.
- A vasodilator should not be used alone as this can increase shear force.
- Labetalol is a good agent as it provides both beta blockade and vasodilatation as one agent.



Preeclampsia/eclampsia

- Diastolic pressure should be reduced to 90-100 mmHg.
- Precipitous drops should be avoided as they may compromise placental circulation.
- Hydralazine and labetalol are the usual agents of choice. Nifedipine can also be used.
- ACE inhibitors should not be used due to adverse fetal effects.



Take home messages

- Hypertensive emergency is a serious event that should be promptly diagnosed and managed.
- The factor of time is of utmost importance in these cases.
- Intravenous options are several and should be tailored according to the case.
- Investigating the cause of hypertension and target organ damage is essential for correct immediate and final management.

An aerial photograph of a university campus. The scene is dominated by lush greenery, including numerous tall palm trees and various shrubs. A paved road curves through the center, with a red car visible on the left. A central monument, a large stone structure with a triangular top, sits on a grassy area. A string of flags in various colors (green, white, blue) is strung across the road. The overall atmosphere is bright and sunny.

THANK YOU

مركز تقنية الاتصالات والمعلومات - جامعة المنصورة