

Approach To A Case Of Heart Burn

Mahmoud Osman M.D.
Prof. Of Medicine
Ain Shams University
Cairo

- GERD is one of the common GI diseases widespread all over the world.
- Heart burn is the golden symptom of GERD.
- The pragmatic approach to manage typical heart burn with no exertional symptoms or alarm signs is giving PPI.

- If there is no good response to treatment (with twice daily dose of PPI) or there is +ve alarm signs → investigate for proper diagnosis and for identification of complications of reflux disease.

- **Endoscopy** is the first test to evaluate the esophageal mucosa for the presence of erosive esophagitis, to screen and biopsy for Barrett's esophagus, and to rule out other diseases e.g ulcers , infectious esophagitis.

Endoscopy

```
graph TD; Endoscopy --> GERD; Endoscopy --> NERD; GERD --- GERD_Pct[40%]; NERD --- NERD_Pct[60%]; GERD --- GERD_List["- Adjust the dose of PPI<br/>- Shift or add drug"]; NERD --- NERD_List["- Some patients with FD or IBS c/o of heart burn"];
```

GERD

40%

- Adjust the dose of PPI
- Shift or add drug

NERD

60%

- Some patients with FD or IBS c/o of heart burn

Stable GERD symptoms do not warrant surveillance endoscopy

Ambulatory pH monitoring is the best way to evaluate patients :

- For the presence of acid reflux (after withholding PPI).
- Determine whether reflux occurs during day or night .
- Correlate the presence of reflux with symptoms.

• Pandoflino et al,2003



Trans nasal pH monitoring for 24 hours is somewhat inconvenient for patients. Shorter time (12 hours) with comparable results would be feasible with placing the tube late in afternoon and removal early the next morning.

Hila et al ,2004

- It is the absolute way to document the effectiveness of PPI (up to 80% of patients continue to secrete some acid even on twice daily PPI therapy).
- So, pH monitoring can distinguish between patients with refractory GERD from patients with hypersensitivity or functional disease.

Wireless capsule pH monitoring (**BRAVO**) which uses a “telemetry capsule” – based monitoring system can perform 48 hours pH monitoring. It is placed 6 cm above z-line by sedated endoscopy or non endoscopic applicator.

Lacy et al, 2004

Multichannel intra luminal **Impedance** monitoring
→ measurement of changes in resistance to
alternating current between 2 electrodes allows the
measurement of bolus movement either antegrade
or retrograde.

Tutuian et al ,2003

- It is the most effective way to evaluate patients with GERD-related symptoms who continue to be symptomatic despite high dose PPI therapy.
- The symptom index (+ve > 50%) is calculated and multiple symptoms can be evaluated: heart burn, regurgitation , cough, hoarseness of voice, globus, epigastric pain and chocking.

Symptom Index

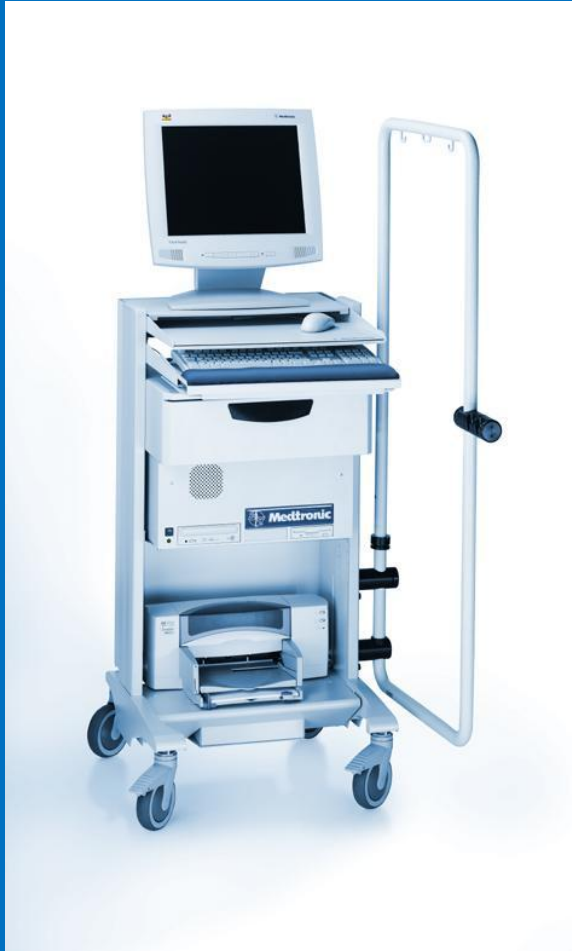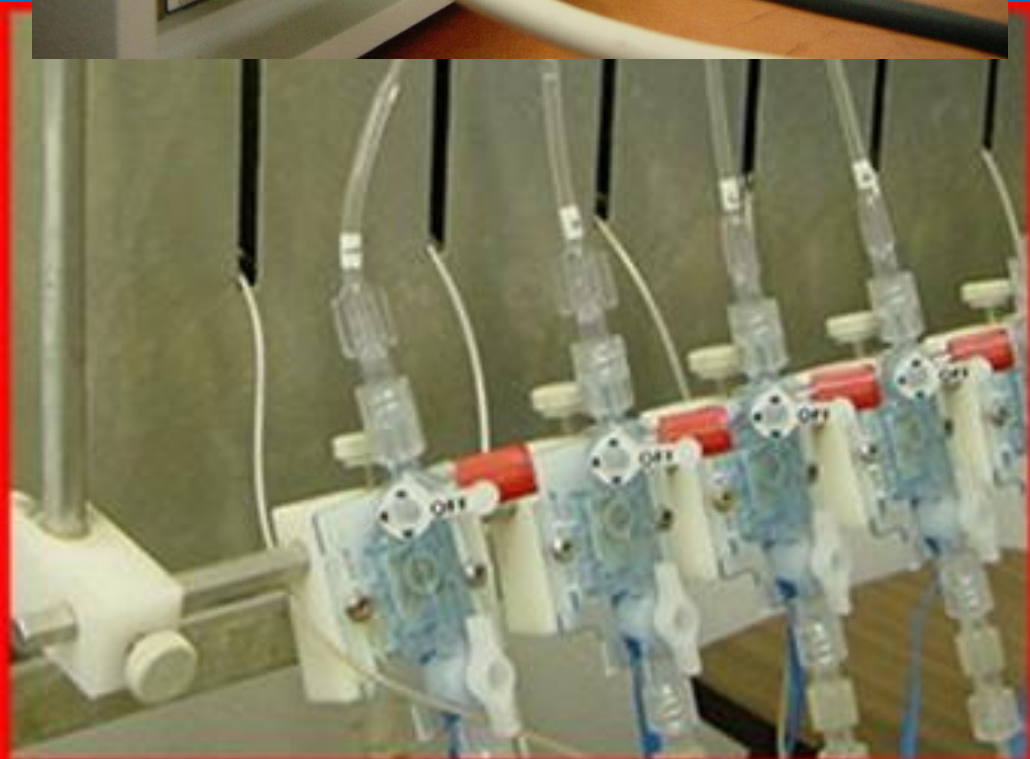
NO. of attacks with reflux episodes/100


Total no. of attacks

+ve if more than 50%

When impedance is combined with pH monitoring on a single catheter it can determine whether the patient is having reflux of either acidic (pH <4) or non acidic (pH > 4) contents.

- Motility study diagnose patients with achalasia who have symptoms that overlap with GERD.
- Conventional manometry is a test used to measure the changes in pressure within the gut, caused by the contractions of the muscles surrounding it.





+20V
+12V
-12V

Stabiliser 3691 PDA 3380 PDA 3380 PDA 3380 PDA 3380 PDA 3380

FS1/2
5 AMP A/S

SECONDS
MINUTES
HOURS
RESET

CHART SPEED
ON
OFF
25 50 100

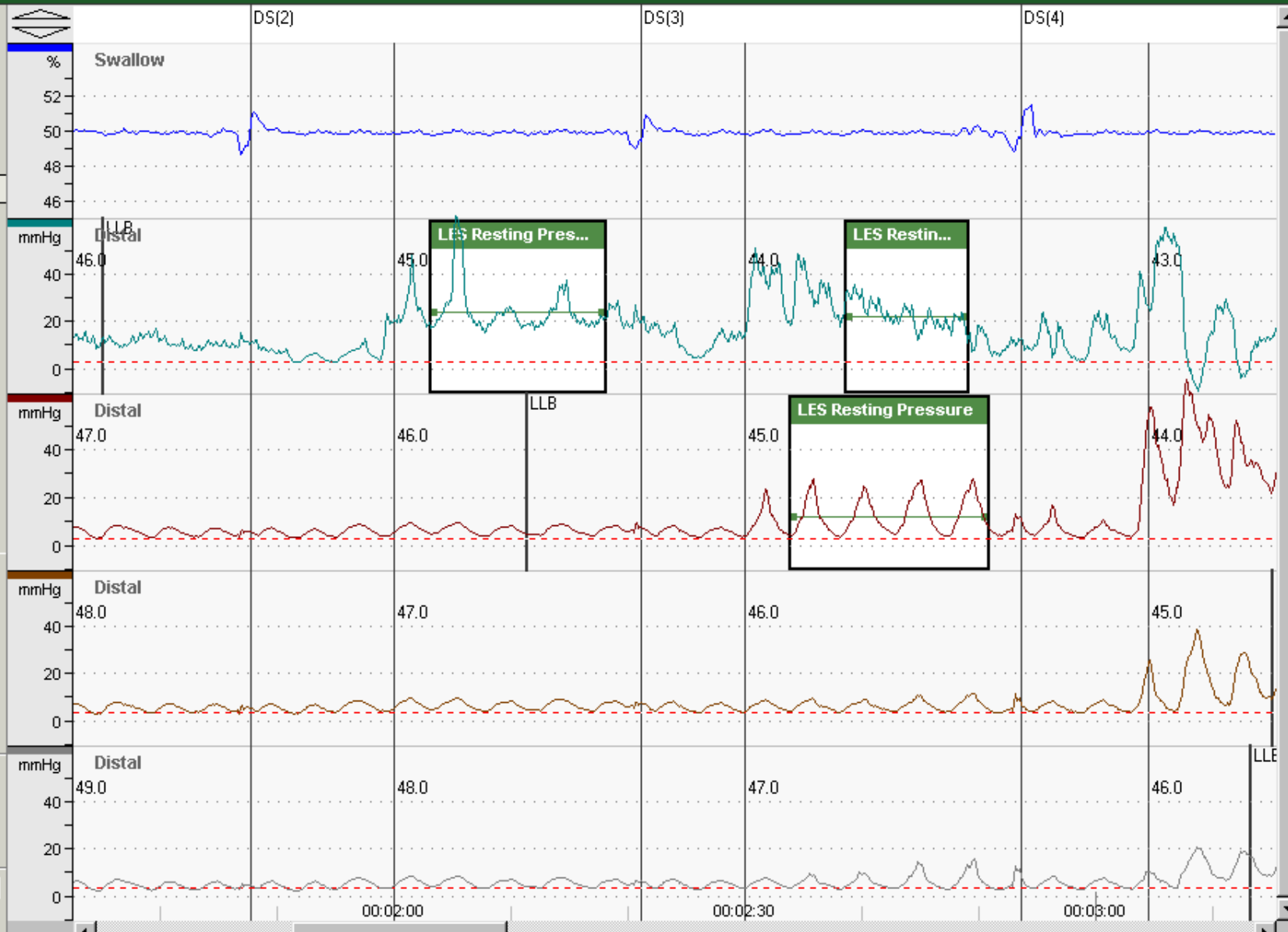
MARKER HEAT
EVENT MARKER LIFT

ectromed

Chart Control

Normal 3rec, Exampel 12 EM - [Esophageal Manometry 17-10-00 12:18]

- STUDY DETAILS
- EQUIPMENT
- CAPTURE
- REVIEW
 - LES
 - Esophageal Body
 - UES
- REPORT
- PROTOCOL



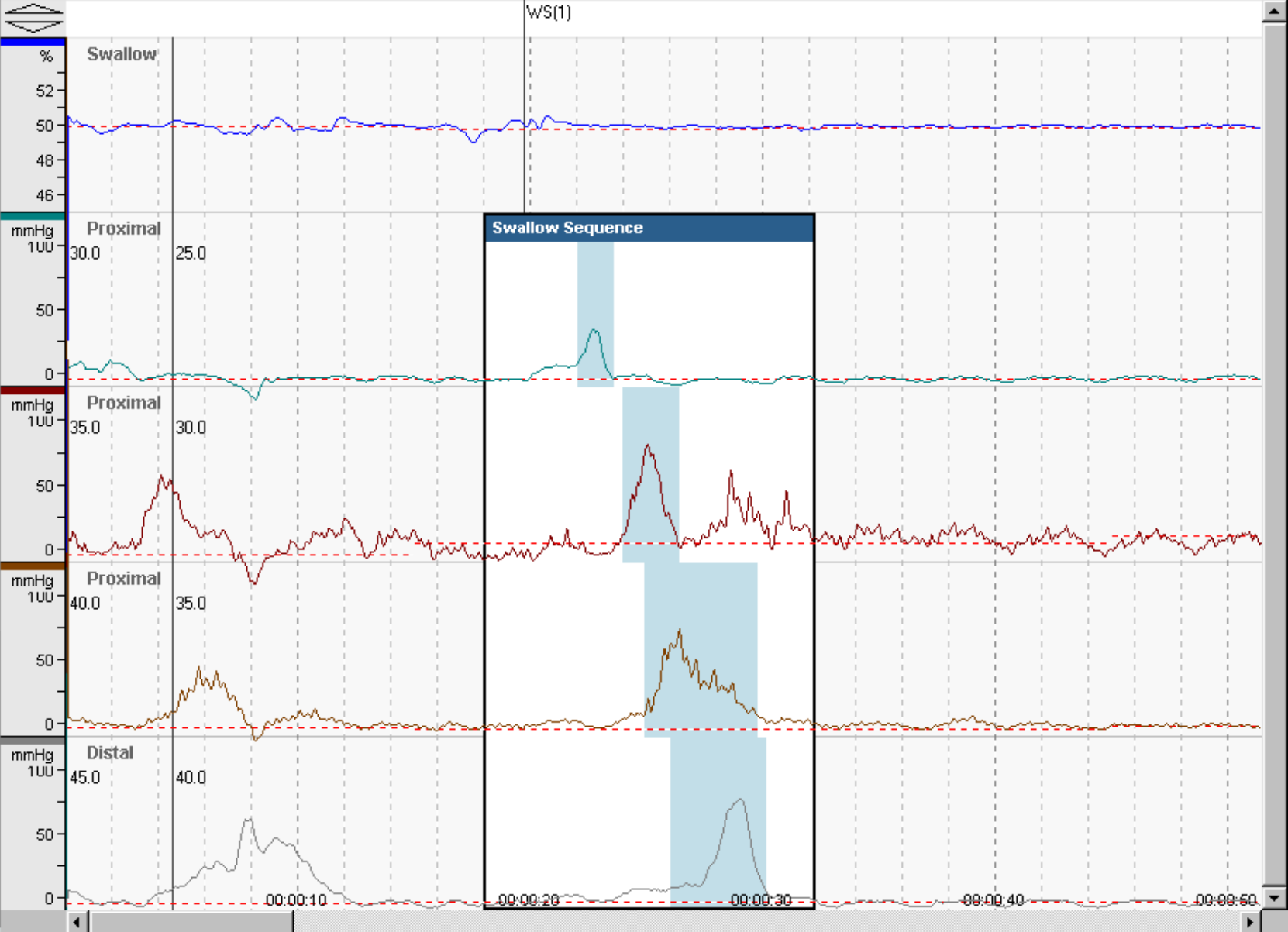
Markers

Tools

Text

Normal 3rec, Exampel 12 EM - [Esophageal Manometry 17-10-00 12:18]

- STUDY DETAILS
- EQUIPMENT
- CAPTURE
- REVIEW
- LES
- Esophageal Body
- UES
- REPORT
- PROTOCOL



Markers

- Red dashed line
- Blue line
- Green line

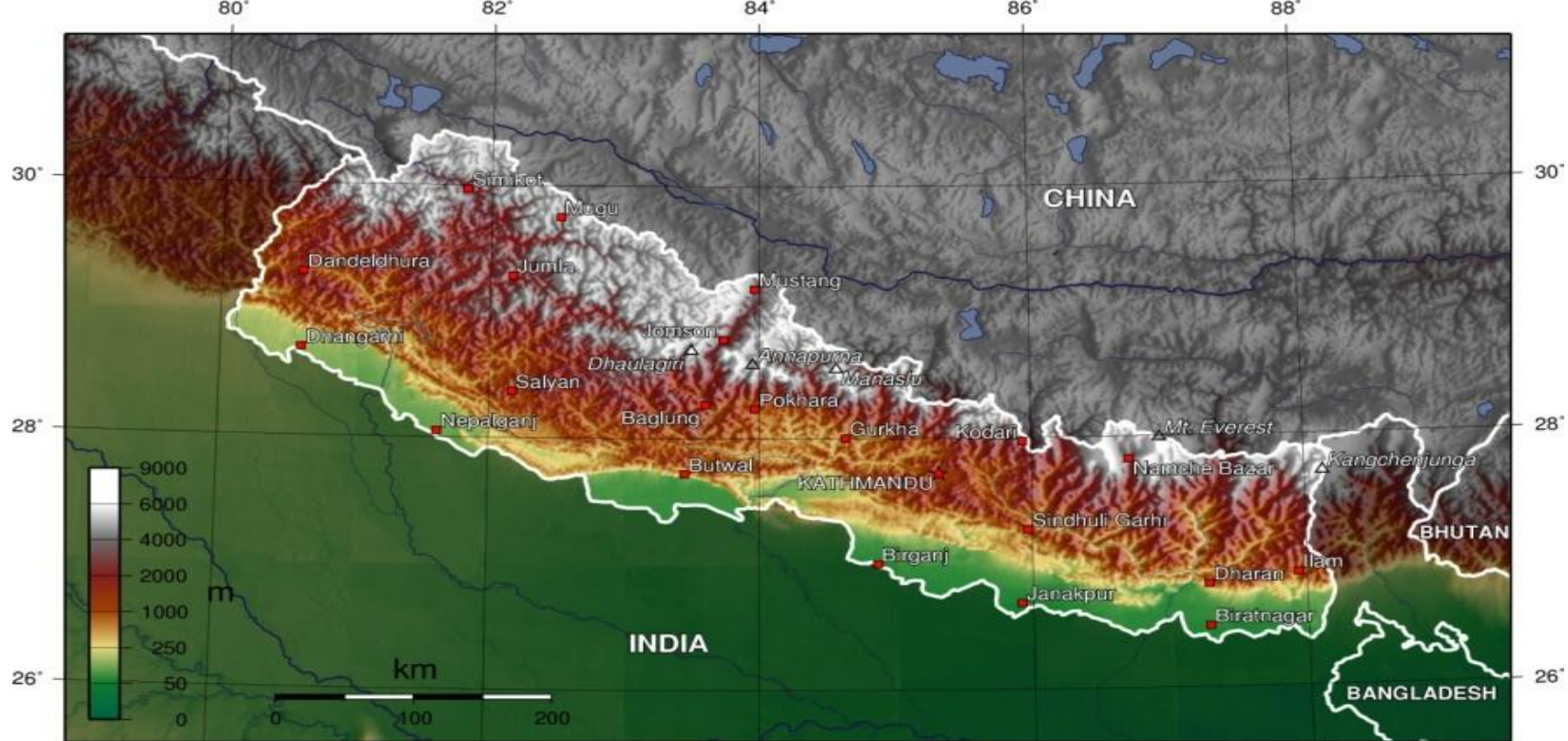
Tools

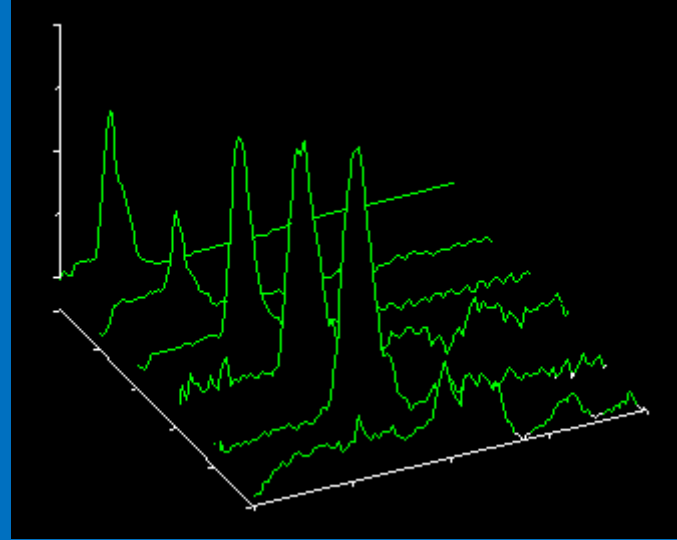
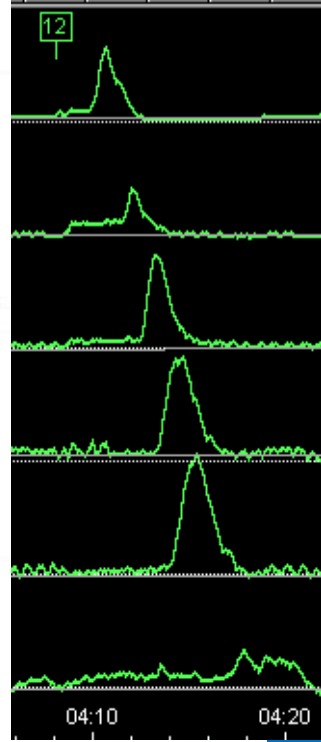
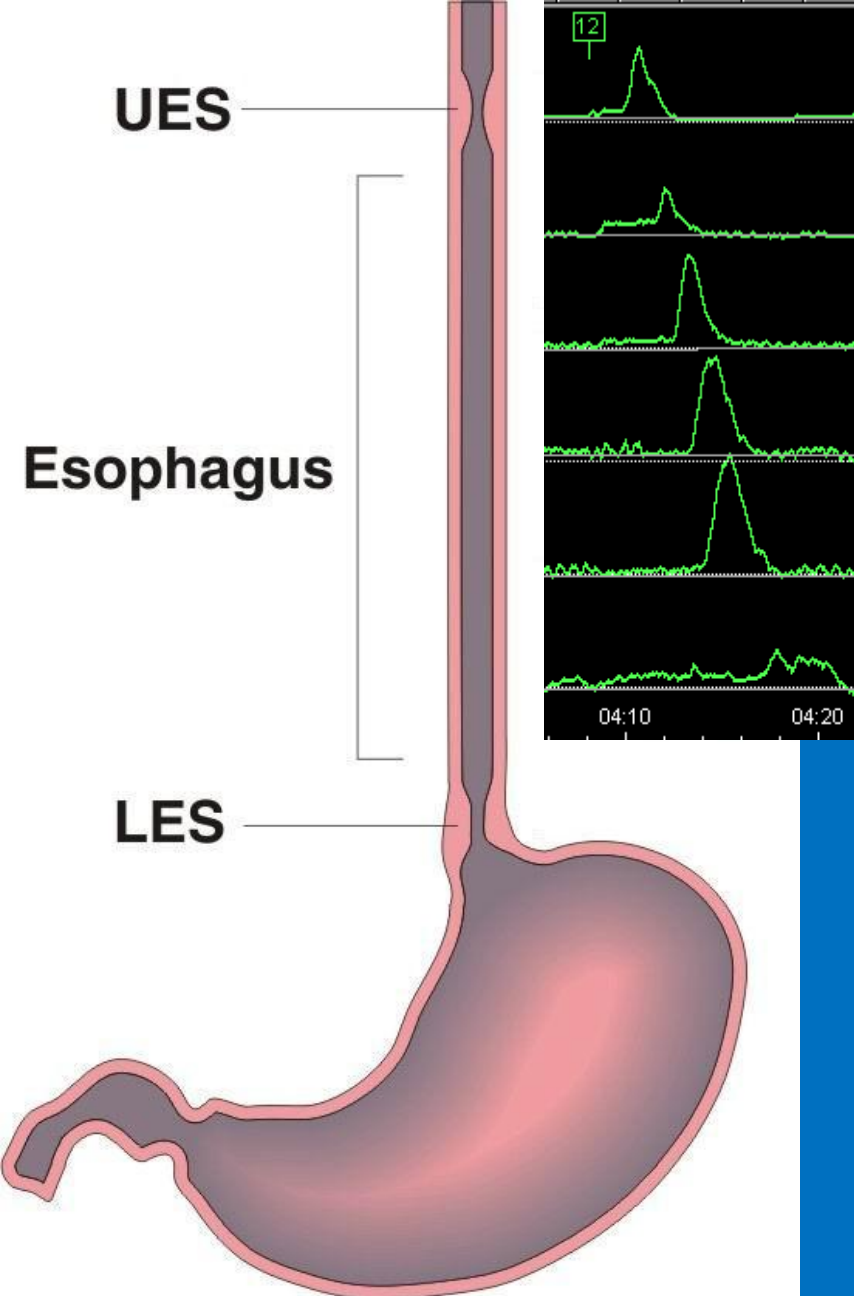
- Mouse cursor
- Text box
- Eraser
- Selection tool
- Zoom in (+)
- Zoom out (-)

Text

Navigation: Left arrow, Right arrow, Home, End

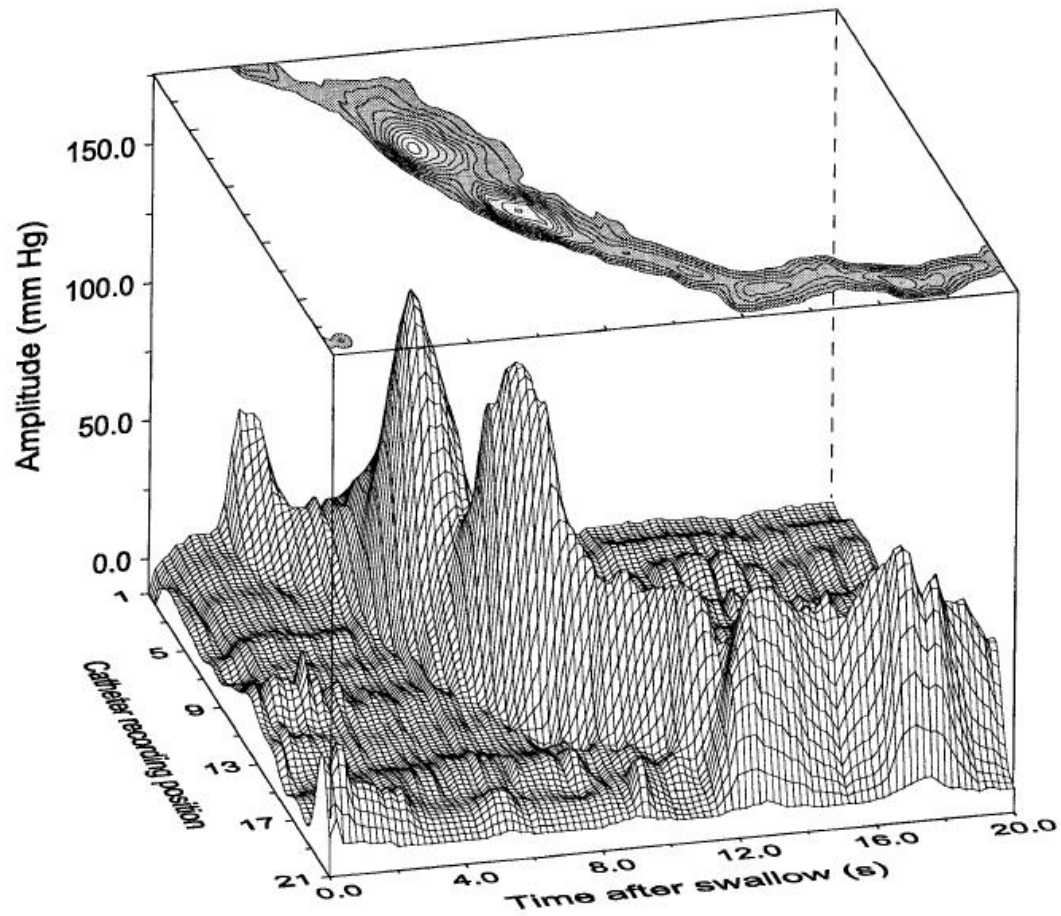
- High resolution manometry (HRM) is the most recent tool for measuring esophageal motility.
- HRM/ Clouse contour plot is a unique display method which was developed by Dr. Ray Clouse (Washington University) and based on topographic surface maps of the earth.

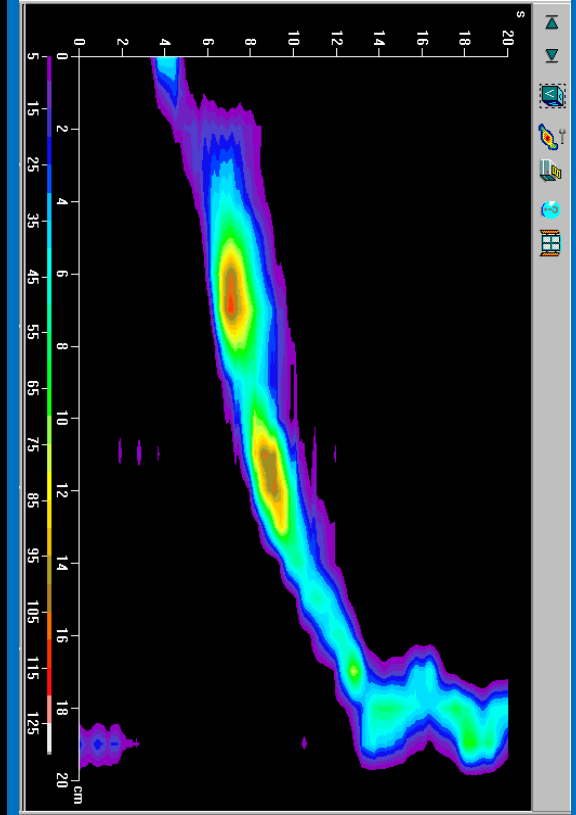
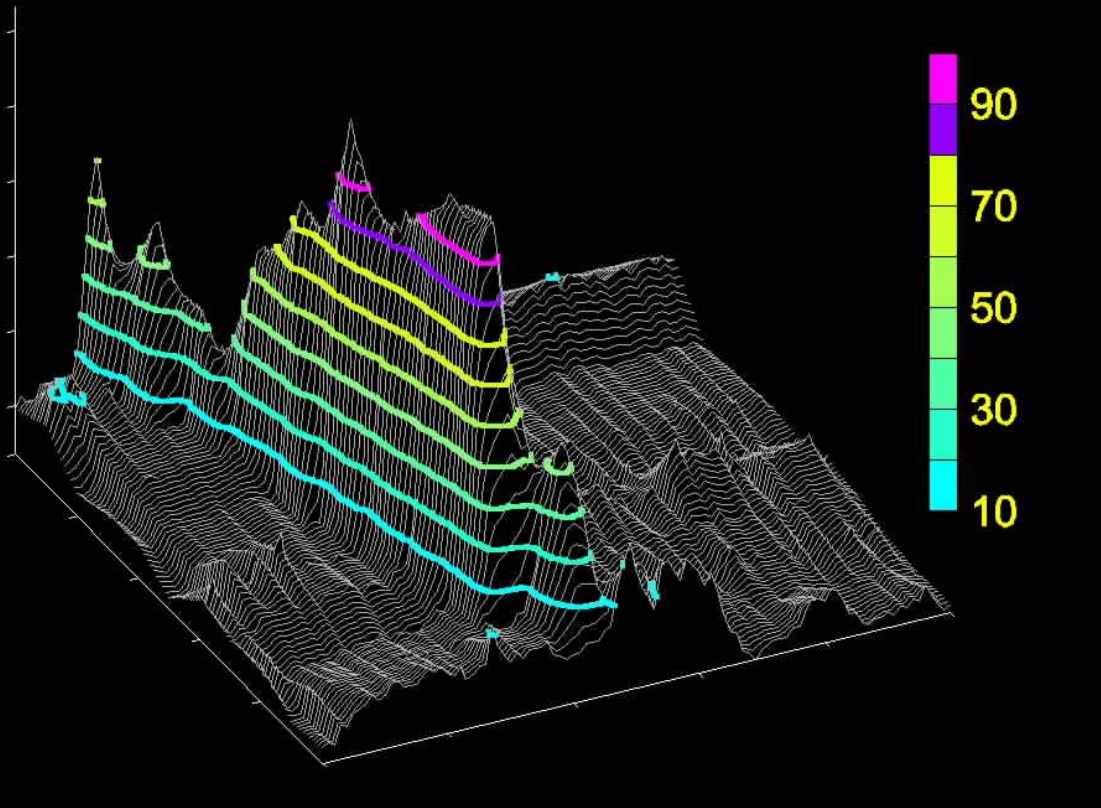




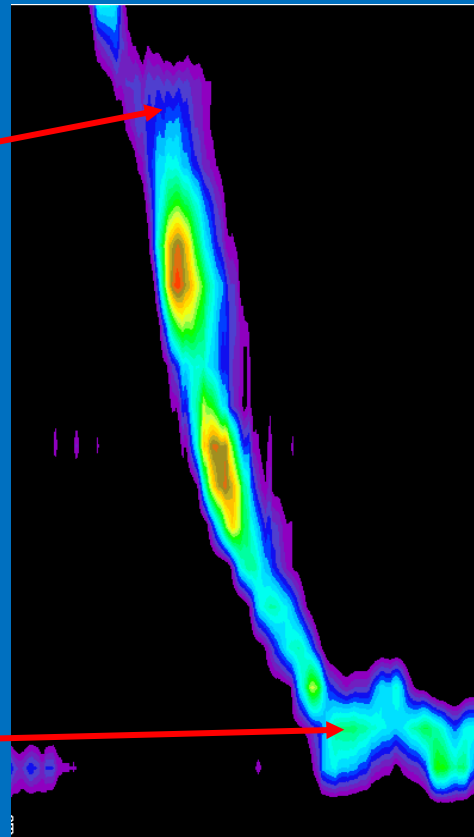
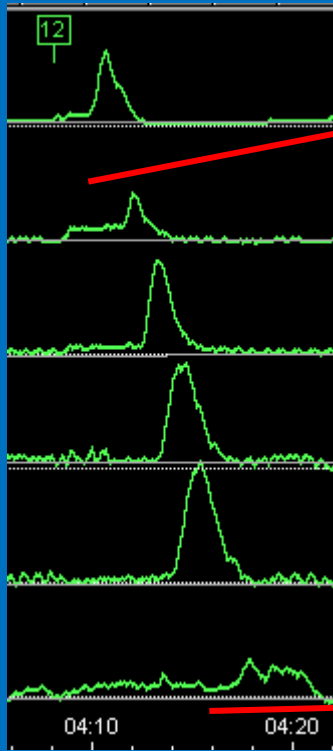
Display pressures in 3-D plane

Look from the top (use a helicopter)

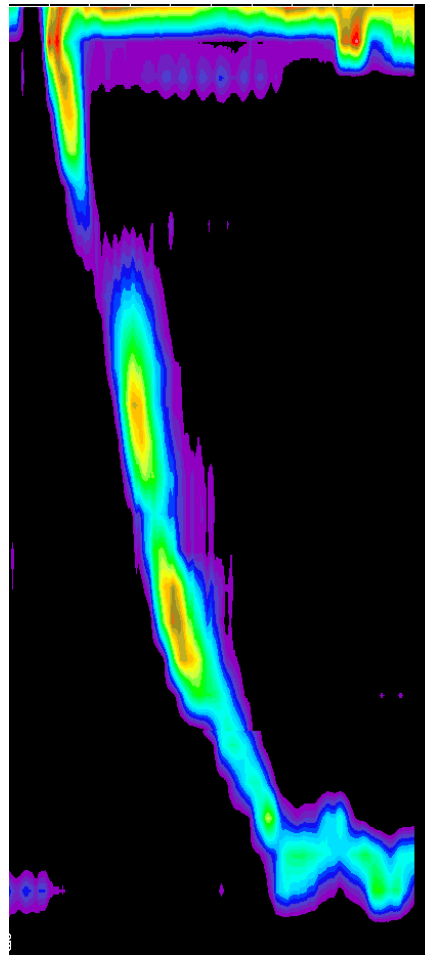
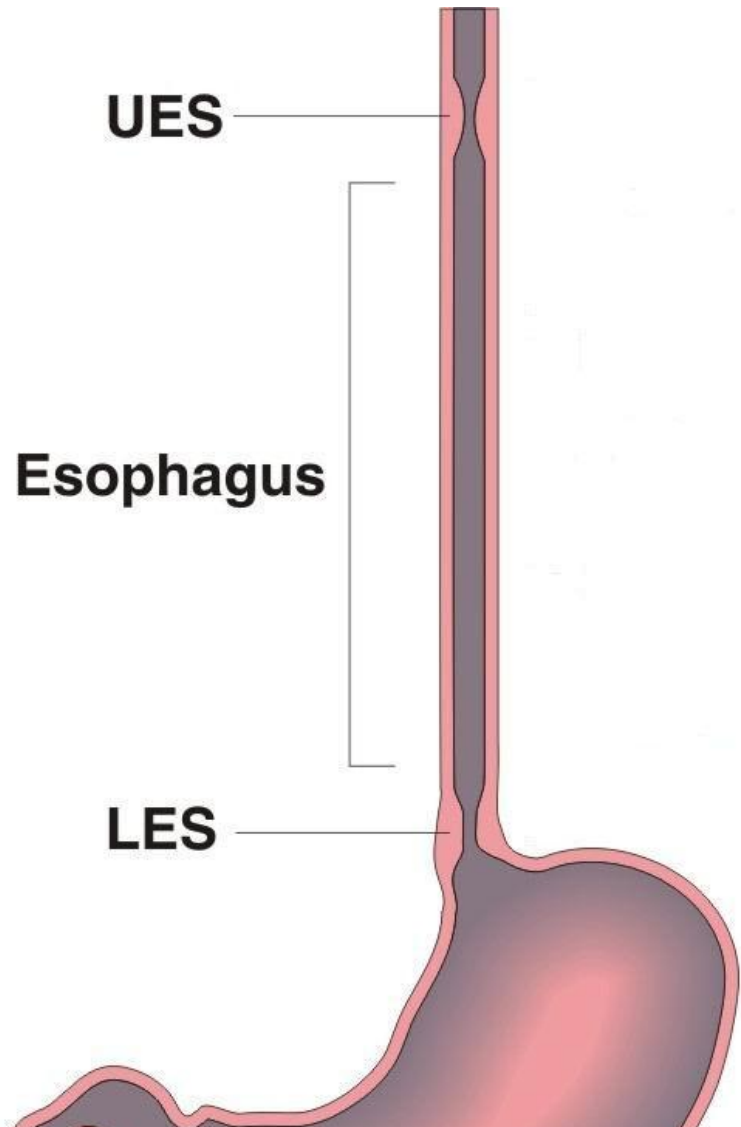




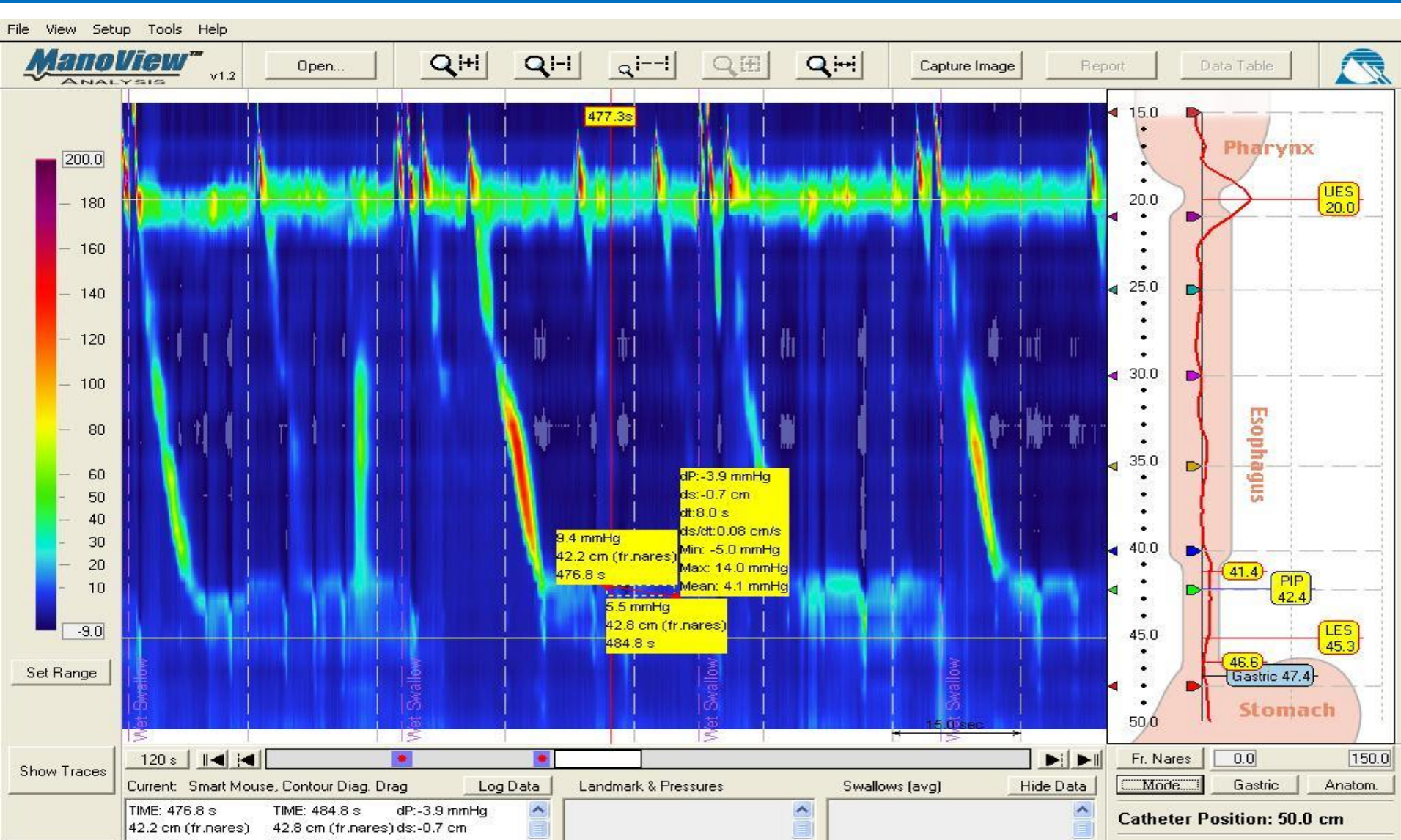
Replace pressure levels by colors



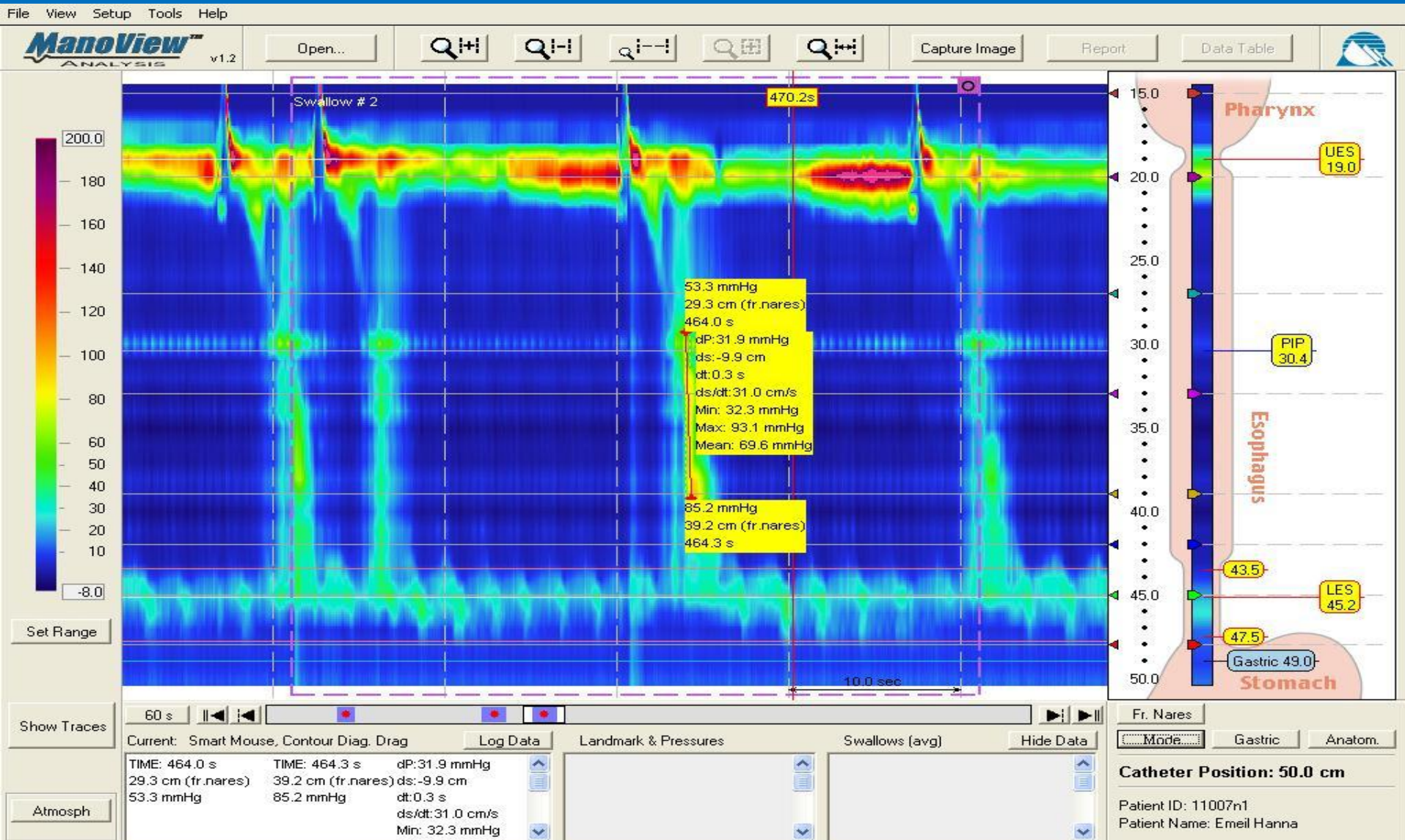
2 landmarks UES and LES (easy)



Ineffective Esophageal Motility



Achalasia



Surgery does have a role !!!!

Conclusion

- Evaluation of the patient with GERD must be individualized.
- Both acid and non acid reflux can be assessed simultaneously with well tolerated trans nasal study.
- Recent modalities can expand and facilitate the study of this wide spread GI disorder.

THANK YOU